

## Complicated tracheo-bronchial papillomatosis

Walid Abu Arab<sup>a,b,#</sup>, Derrar Alshehab<sup>a#</sup>, Hassan Jamal Eddine<sup>a#</sup>, Adel Ayed<sup>a,c#</sup>

<sup>a</sup>Thoracic Surgery Unit, Chest Disease Hospital, Kuwait.

<sup>b</sup>Cardiothoracic Surgery Department, Faculty of Medicine of Alexandria, Egypt.

<sup>c</sup>Department of Surgery, Faculty of Medicine, University of Kuwait, Kuwait.

### Abstract

Respiratory papillomas are rare benign lesions. They are characterized by the appearance of papillomatous lesions anywhere in the tracheo-bronchial tree. It affects children and young adults. Although the disease affects mainly the upper airways, it may be aggressive and extends distally to the lower respiratory tract and pulmonary parenchyma. The course of the disease is unpredictable. It may regress spontaneously, but in other instances, it may lead to serious complications ranging from airway obstruction up to malignant transformation. Surgical excision is the mainstay of definitive treatment to prevent recurrence and to exclude malignancy. We have reviewed the literature for this rare type of respiratory disease and present a thirty-five years old; male patient who had chronic cough and was referred to our unit with a CT-chest that revealed left main endo-bronchial lesion. Bronchoscopy and biopsy of the lesion were performed and revealed squamous papilloma. Final treatment introduced to the patient was endoscopic thermal ablation. However, the final pathology revealed complicated squamous bronchial papilloma with infection by aspergillosis and actinomycosis.

**Keywords:** HPV; Tracheo-bronchial papillomatosis; endo-bronchial lesion; bronchoscopy

### BACKGROUND

Pulmonary papillomas are rare types of lung neoplasms. They are classified into three groups<sup>[1,2]</sup>. The first group is composed of multiple papillomatoses, which usually affect the larynx, predominantly in children. Juvenile laryngo-tracheal papillomatosis rarely involves the lower respiratory tree. These types of papillomas are usually related to the infection by human papilloma virus (HPV). Although they frequently recur, they have a tendency to regress spontaneously after puberty. The second group includes inflammatory endo-bronchial polyps. These inflammatory polyps usually arise from the mucosa in patients with chronic respiratory infection. These polyps are covered by respiratory ciliated epithelium. They may show focal squamous metaplasia, and may contain edematous fibrous tissue core with granulation-like tissue and inflammatory cells. The third group of lesions includes the solitary trachea-bronchial papillomas (STBP). It is rare type and constitutes less than 0.5% of lung tumors<sup>[1]</sup>.

Pulmonary papilloma usually presents as an endo-bron-

chial lesion in the segmental bronchi. They can be divided histologically into squamous cell, glandular and mixed type papillomas<sup>[2,3]</sup>. Squamous papilloma is characterized by a bimodal age distribution. The young children and young adults are the most commonly affected<sup>[4,5]</sup>. The disease is common at age of childhood. The virus is thought to be transmitted vertically through the contact with infected secretions in the birth canal. However, in adults, the HPV infection may occur following oral sex<sup>[5-7]</sup>. The histological presentation is benign squamous epithelial stratification<sup>[7]</sup>. However, respiratory papillomas are considered as tumors of low potential malignancy as they may present with dysplasia, and they have a recurrence rate around 20 % with the potential to transform into squamous cell carcinoma<sup>[2]</sup>. Respiratory papilloma is typically restricted to the larynx, but in some occasions, it presents with aggressive behavior, resulting in persistent or recurrent involvement of the naso-pharynx, trachea-bronchial tree and rarely, the pulmonary parenchyma<sup>[7-9]</sup>. Respiratory papillomatosis is a disease of unpredictable course that ranges from spontaneous remission to aggressive behavior, spreading to the lungs and may require multiple surgical procedures to maintain functional airway<sup>[10]</sup>. Diagnosis of respiratory papilloma could be suspected from the clinical presentation and imaging findings, however the final diagnosis is based mainly on histo-pathological examination obtained via biopsy of the lesion<sup>[7]</sup>.

<sup>#</sup>These authors contributed equally.

\*Corresponding author: Prof. Walid Abu Arab  
Cardiothoracic Surgery Department, Faculty of Medicine  
Middan Al-khartoum, Alexandria, Egypt  
E-mail: walidabuarab@yahoo.com

Received: 29 July 2019 Accepted: 05 September 2019

The glandular and mixed types of papillomas are seen in older men. They are less commonly associated with smoking. Squamous cell papilloma can be exophytic, or inverted. Microscopically they resemble viral papillomas that are seen in the genito-perineal region. Glandular papillomas can be lined by ciliated and non-ciliated columnar cells, including occasional goblet cells. Mixed papillomas were named before transitional papillomas. Patients can be asymptomatic and discovered incidentally or can present either with obstructive symptoms, or hemoptysis<sup>[2]</sup>.

## ETIOLOGY

Respiratory papillomatosis has been linked to HPV infection. Studies have revealed that there are more than 180 genotypes of HPV. They have a specific affinity for squamous epithelial cells in different tissues. Consequently, the infection with HPV can result into different clinical manifestations<sup>[4,6]</sup>. HPV has been associated with many benign and malignant tumors of epidermal origin. It is associated with cancer of the cervix, tumors of head and neck, and ano-genital tumors<sup>[11]</sup>.

There are different subtypes of HPV<sup>[5, 12]</sup>. The subtypes 6 and 11 are involved in more than 90 % of recurrent respiratory papillomatosis<sup>[6, 13]</sup>. However, type 11 of HPV is implicated in the development of the more aggressive disease<sup>[12]</sup>. The subtypes 16 and 18 of the HPV are considered to be associated with a high risk of transformation into malignant disease, specifically into squamous cell carcinoma<sup>[6, 7, 14]</sup>.

## PREVALENCE AND EPIDEMIOLOGY

Respiratory papillomatosis can be presented either during childhood or at early adulthood<sup>[5, 10, 15]</sup>. The respiratory papillomatosis that occur in young patients; less than twenty years; is called juvenile form<sup>[7, 16]</sup>. This juvenile form usually include development of multiple papillomatous lesions of aggressive behavior with a high rate of recurrence<sup>[7, 13]</sup>. On the other hand, the form that occurs in patients over the age of twenty; in the third and fourth decades of life; is called adult form of respiratory papillomatosis<sup>[7, 11, 17]</sup>. It is usually encountered in males. The papillomas occurring in adult form are usually solitary and they do not spread. Moreover, their recurrence rate is lesser than that of juvenile form<sup>[13]</sup>.

The incidence of respiratory papillomas is varying according to its form. The incidence of the juvenile form is about 4 per 100,000, however; the incidence of the adult form is 2 per 100,000<sup>[5, 11, 13, 15, 16]</sup>. There are some factors that affect the incidence of respiratory papilloma. They include age, socioeconomic status and education level<sup>[4, 5]</sup>. It was found that respiratory papilloma incidence is higher in those with of low socioeconomic status and low educational levels<sup>[4, 10]</sup>.

Infection with HPV in children occurs mostly during birth through passage via the birth canals of infected mothers<sup>[5, 6-8]</sup>. The transmission of infection may occur prior to birth, through the placenta, in approximately 12% of cases<sup>[4, 10]</sup>. One of the primary risk factors for the development of juvenile form of respiratory papillomas is the presence of maternal ano-genital warts during pregnancy<sup>[4, 6]</sup>. Approximately, less than 1 % of infants who have been exposed to maternal ano-genital warts developed respiratory papillomatosis<sup>[6, 10, 18]</sup>. In adult patients, the HPV is mostly transmitted sexually, usually through oral sex<sup>[5-7]</sup>. Moreover, the risk of infection in adults increases if the patients have sexual activity with multiple partners<sup>[6]</sup>.

## PATHOGENESIS

HPV infection occurs through contact of minor exco-riated mucous or cutaneous surfaces with a source of infection. The virus initially infects the basal epithelial layer<sup>[13]</sup>. Following infection of the basal epithelial layer, the HPV activates the epidermal growth factor receptor pathway and deactivates many of the tumor-suppressing proteins, resulting in cellular proliferation and epithelial differentiation. The final result is production of "cauliflower-like" exophytic lesions of the respiratory papilloma<sup>[6, 13]</sup>. Mostly, these lesions are located at the transitional areas between the squamous epithelium and the ciliated columnar one<sup>[6, 11, 13, 19]</sup>.

Papillomas can present as solitary or multiple nodules. The nodules can be either exophytic, sessile or pedunculated lesions. Majority of the lesions; generally appear affecting the larynx<sup>[13]</sup>. However, they may affect any part of the aero-digestive tract and even may extend to the trachea-bronchial tree and pulmonary parenchyma<sup>[7, 13, 20]</sup>. Affection and extension to the distal airway occurs in approximately 2-5 % of cases<sup>[7, 9, 20, 21]</sup>.

Distal spread of the laryngeal papillomatosis has not been explained. Different theories to explain this distal spread have been postulated. They include the extension of papillomas by contiguity, diffuse viral contamination, and iatrogenic factors. The iatrogenic factors include laryngoscopy, bronchoscopy, tracheostomy, and surgical manipulation<sup>[7, 9]</sup>. Furthermore, there are high-risk factors that are implicated in the distal spread of respiratory papillomatosis. These risk factors include infection with HPV-11, age above 3 years, tracheostomy performed to avoid airway obstruction, and the previous invasive procedures<sup>[6, 18]</sup>.

Although it is rare, the respiratory papillomatosis can be transformed into bronchogenic squamous cell carcinoma<sup>[7, 8, 13]</sup>. This malignant transformation can occur decades after the disease onset, generally in patients with prior spreading to the tracheobronchial tree. Moreover, malignant transformation occurs very infrequently in

the laryngeal form of the disease, without involvement of the distal airway<sup>[7]</sup>. The rate of malignant transformation is less than 1% in children and is between 3 and 7% in adults<sup>[13]</sup>. The risk factors involved in the malignant transformation include infection with high-risk HPV subtypes 16 and 18, smoking, previous radiotherapy or the use of cytotoxic drugs, p53 gene mutation, and high severity score or high activity of 20-5'-oligoadenylate synthetase<sup>[7, 12]</sup>. The mechanism by which the malignant transformation develops is unclear. However, some studies attributed the oncological effect of the HPV is related to its interference in the cellular cycle, which consequently alters the control of cellular differentiation<sup>[7, 10, 11, 13]</sup>.

## CLINICAL PRESENTATION

The clinical presentation is not typical for all patients as the course of the diseases of respiratory papillomatosis is variable. Spontaneous remission sometimes occurs in a minority of patients. However, in majority of cases, it takes an aggressive course that requires multiple interventions<sup>[13, 22]</sup>. In adults, as many of pulmonary illnesses, the respiratory papillomatosis usually presents with non-specific symptoms of airway involvement. The symptoms may include chronic cough that is in most of instances not responding to symptomatic treatment. Also, change of voice or hoarseness may be present. Furthermore, wheezing, dyspnea and stridor may occur<sup>[6, 7, 13, 22]</sup>. Meanwhile, in children, characteristically, the clinical presentation of respiratory papillomatosis is composed of a triad of progressive hoarseness, stridor, and dyspnea<sup>[4]</sup>.

The hoarseness of voice is the most common symptom in adults<sup>[7]</sup>. Other symptoms and signs may be present like wheezing, tachypnea, and stridor<sup>[6, 7]</sup>. Furthermore, clinical picture can be more severe in presentation, and patients may present with airway obstruction and severe respiratory distress<sup>[6, 7, 13]</sup>. Hence, Respiratory papillomatosis can be misdiagnosed easily or discovered late due to its nonspecific clinical presentations and unpredictable course that mimics most of the common laryngeal and respiratory diseases<sup>[13, 22]</sup>. Most of the patients are not diagnosed on the first presentation and they are treated for the presenting symptoms and signs, hence they do not respond, and the symptoms worsen. The disease then may evolve to severe respiratory distress due to airway obstruction<sup>[4, 9]</sup>. Respiratory papillomatosis is a benign disease; however, it may lead to a significant morbidity and may cause mortality in some instances due to high rate of recurrence and the possibility to spread all over the respiratory tract<sup>[4]</sup>. Progressive disease with peripheral dissemination may lead to recurrent small airway obstruction with subsequent obstructive atelectasis and pneumonia. Even more, malignant degeneration may result eventually. Hemoptysis is a common presentation

in patients with respiratory papillomatosis. Hence, it is usually confused with active pulmonary tuberculosis<sup>[23]</sup>. In the juvenile form of the respiratory papillomatosis, the clinical presentation tends to be more severe due to rapid growth of the lesions and airway obstruction<sup>[4, 5]</sup>. As the course of the disease is unpredictable and may worsen at any time. Some children require follow-up every six months while others need more frequent follow-up visits or even admissions due to the progressive disease<sup>[4, 22]</sup>.

## DIAGNOSIS

Respiratory papillomatosis is usually not diagnosed by clinical presentation or by the findings on the chest X-ray (CXR)<sup>[4, 6]</sup>. In patients who had a progressive disease, a solid or cavitated pulmonary nodules may be shown at the CXR. On rare occasions, sessile or pedunculated nodular lesions can be detected inside the trachea-bronchial tree on CXR<sup>[4, 7]</sup>. Computed tomography of the Chest (CT-Chest) is considered the radiological test of choice to assess this entity of pulmonary pathology. It is accurate in the identification and characterization of trachea-bronchial and pulmonary lesions<sup>[9]</sup>. The radiological findings in the CT-chest may suggest a diagnosis of papillomatosis at the trachea or the bronchi<sup>[4, 7]</sup>. CT-Chest findings may include focal or diffuse airway narrowing caused by the nodular lesions. These lesions may be located on the mucosal surface or even projecting into the airway lumen. The involvement of pulmonary tissue with respiratory papillomatosis may be manifested in the CT by the presence of a single or multiple well defined, multilobulated, solid nodular or polypoid lesions of different sizes. These lesions usually have centrilobular distribution, and are scattered throughout the lungs. Some nodules may enlarge in size and transform into air-filled cysts leading to the formation of large cavities with irregular internal borders and thick or thin walls<sup>[7, 9, 23]</sup>. The nodular lesions in the lung usually affect more the basal and posterior parts. Those lesions that developed cavities are usually get infected. Other findings that may be detected in CT-Chest are usually related to the secondary effects or the complications of respiratory papillomatosis. These findings may be due to airway obstruction and secondary infections, atelectasis, consolidation, air trapping, or bronchiectasis. The lymph node enlargement and pleural effusion are not frequently encountered, except in patients who developed malignant transformation<sup>[7, 9]</sup>.

On occurrence of malignant transformation, CT-Chest may show enlargement of pulmonary nodular lesions, nodules at the bronchi, or the trachea. This enlargement of the lesions may be associated with numerous enlarged lymph nodes at mediastinum and neck<sup>[4, 24]</sup>. The virtual bronchoscopy is found to be a useful tool in the

assessment the disease affecting the air-way. It enables three-dimensional visualization of the airways<sup>[4]</sup>. Virtual bronchoscopy has an advantage of avoiding the potential complications of the conventional bronchoscopy. Moreover, it enables visualization and assessment of the distal airways beyond and endo-luminal stricture if present<sup>[4, 8]</sup>. Magnetic resonance imaging (MRI) can show laryngeal, trachea-bronchial, and pulmonary lesions. However, its role in the diagnosis of respiratory papillomatosis has not been definitely established<sup>[25]</sup>. Positron Emission Tomography (PET- Scan) has no a major role in the diagnosis of respiratory papillomatosis or in the early detection of the malignancy associated with these lesions. However, it may show an elevated uptake of the lesion due to elevated cellular proliferation<sup>[24, 26]</sup>. The direct laryngoscopy and fiberoptic bronchoscopy are the gold standard ways to confirm the diagnosis of respiratory papillomatosis. Bronchoscopy is the most reliable method for the diagnosis of trachea-bronchial papillomatous lesions because it allows direct visualization of the lesions with direct assessment of the coloration of the trachea-bronchial mucosa. Furthermore, biopsy of the lesions can be performed. This is important for histo-pathological diagnosis and viral typing. In addition, bronchoscopy is an important step in the treatment planning. Papilloma lesions can be seen as whitish polypoidal masses with clean and smooth surfaces during bronchoscopy. They may be localized in the larynx, trachea, or bronchi<sup>[7, 10, 20]</sup>. Histopathological examination of these lesions is the best way for definitive diagnosis of the respiratory papillomatosis<sup>[7, 22]</sup>.

## **PATHOLOGY**

Respiratory papillomas usually present as exophytic soft and friable nodules or masses. They may be sessile or pedunculated, soft, and friable. Microscopic papilloma appears with velvety mucosa over, while the mucosa appears pinkish-whitish "cauliflower-like" with the exophytic papilloma<sup>[10]</sup>.

On histo-pathological examination, papillomas appear as projections or multiple fronds that have central fibro-vascular cores and covered by stratified squamous epithelium<sup>[10]</sup>. Hyperplasia of the basal cell layer and the large vacuolated epithelial cells are typical findings<sup>[7, 9, 10, 15]</sup>. Basal layer thickening with an increased number of nucleated cells in the supra-basal layer of the stratified epithelium may be detected as the HPV can cause a delay in maturation of the epithelial cells<sup>[4, 15]</sup>. Moreover, histo-pathological examination may reveal abnormal cellular differentiation with abnormal keratin production and expression<sup>[15]</sup>. The papillomatous lesions that extend to the trachea-bronchial tree manifest a squamous or ciliated and cylindrical epithelium<sup>[4, 7]</sup>.

Pulmonary papillomatous lesions are presented in a

different histo-pathological way. They have a different morphology. They may appear as foci of squamous epithelium that grow circumferentially within the alveoli and have blood supply via alveolar vascularisation. The center of the pulmonary papilloma usually shows areas of necrosis and degeneration, while the squamous cells on the periphery invade the adjacent alveoli. These pulmonary lesions grow, coalesce together, and finally destroy the pulmonary parenchyma and forming cavities<sup>[7, 9]</sup>. Papillomas are histologically benign lesions, however; dysplasia and malignant changes may occur<sup>[4, 7]</sup>. If malignant transformation occurs, pathological examination revealed sheets of polygonal tumoral cells with abundant eosinophilic cytoplasm and vesicular nuclei. This is associated with presence of foci of keratinization, atypia, focal necrosis, and a variable mitotic rate, with micro-invasive growth. Immuno-histochemical examination may reveal expression of cytokeratin 5 and 6, which indicate epithelial origin<sup>[25]</sup>.

## **DIFFERENTIAL DIAGNOSIS**

The differential diagnosis of respiratory papilloma includes a wide range of variable respiratory illnesses. It includes many of focal and diffuse central airway diseases<sup>[4, 20]</sup>. Focal lesions may resemble tracheal neoplasms, post-intubation stenosis, traumatic lesions, some infectious diseases, and the systemic diseases that may involve the airways and result in focal trachea-bronchial stenosis<sup>[4, 20, 23]</sup>. The diffuse pulmonary papillomatous lesions should be differentiated from Wegener's granulomatosis, amyloidosis, tracheobronchopathia osteochondroplastica, relapsing poly-chondritis, trachea-bronchomegaly, tuberculosis, neurofibromatosis and sarcoidosis<sup>[20, 23]</sup>.

The diagnosis is established well via bronchoscopy and biopsy of the lesion. However, CT is an important step in evaluation as the lesion location, presence and pattern of calcification, presence of other parenchymal pulmonary lesions may help in the preliminary diagnosis and can help in the planning for bronchoscopy or the therapeutic intervention<sup>[7, 9, 23]</sup>. In summary, the clinical symptoms and signs of central airway involvement, beside the presence of bronchoscopic or CT-findings of tracheal or bronchial wall thickening and irregular narrowing of their lumen, as well as nodular or polypoid non-calcified lesions, are highly suggestive of respiratory papillomatosis. Furthermore, the presence of cavitory pulmonary nodules as a distal spread makes a diagnosis of respiratory papillomatosis more likely. However, the final diagnosis is reached by biopsy and histopathological examination<sup>[4, 5, 20, 23]</sup>.

## **TREATMENT**

Actually, there is no definitive standard curative treat-



ment for the respiratory papilloma. However, surgical excision of the papillomas is considered the mainstay of treatment. The treatment aims at maintaining a functioning clear airway and to keep the quality of phonation [5, 11, 13, 27]. The main goal of the surgical intervention is debulking the papillomatous lesion as much as possible while keeping normal trachea-bronchial airway and pulmonary tissue structures [4, 28]. The conversion into the use of micro-laryngeal surgery and micro-debrider instead of the laser in the debridement was taken place due to the frequent complications associated with laser. These complications include airway burns, laryngeal scarring and stenosis, and trachea-esophageal fistulae [5, 26]. Precise debridement can be performed using micro-debrider with less damage to the underlying tissues and greater preservation of the normal epithelium. However, this modality of treatment needs several sessions and should be repeated [4, 5]. Serious surgical complications can still encountered in spite of the introduction of new techniques in the treatment and a recent advancement in the surgical equipment. These serious complications include laryngeal synechia and glottic or sub-glottic stenosis. Complications usually occur in patients who underwent multiple interventions and several recurrences [5]. Recurrence following surgical ablation is not uncommon. This could be explained by the persistence of the HPV genome in the remaining tissues [4, 13]. In patients with extensive disease and a risk of laryngeal obstruction; tracheostomy may be performed following repeated intervention [5, 11, 12]. Donne et al. [12] documented that HPV subtype 11 is more likely to result in tracheostomy. In those patients who had tracheostomy, de-cannulation should be performed once the airway is considered to be stable and the disease is under control to avoid an additional site for rapid viral colonization and progression of the disease distally [5].

Around one fifth of patients with respiratory papillomas require additional adjuvant medical therapy beside the surgical treatment to control the disease [4, 13]. The adjuvant therapy is not used from the start. The current criteria for adjuvant therapy in patients with respiratory papillomas include the need for more than four surgical interventions per year, rapid recurrence of the lesions that are associated with airway compromise, and distal spread of the disease. Most of medications use is based on immunomodulation and inhibition of HPV proliferation. These include interferon, antiviral agents, retinoids, and oxigenase-2 cycle inhibitors [13].

Interferon is one of the early drugs that were used as an adjuvant treatment for respiratory papilloma. It exhibited positive favorable results in some patients as it resulted in the growth reduction of the lesion [13, 18]. However, its intravenous administration may result in systemic toxicity, possible leucopenia and thrombocy-

topenia [4]. Moreover, it can lead to some adverse effects that include transient fever, fatigue, nausea, arthralgia, headache, and spastic diplegia in infants [5]. Cidofovir is another antiviral medication. It is an analog of cytosine that is currently used commonly as a medical adjuvant drug in the treatment of the respiratory papilloma [5, 22]. It has the advantage to be administered either intravenously, via nebulization, or by intra-lesional injection. The advantage of intra-lesional injection of the cidofovir is the good treatment response where a partial to total regression of lesions occurred. Furthermore, this type of treatment is associated with a reduction of the frequency of surgical interventions [4, 5, 22]. In addition, the intra-lesional administration of cidofovir maintains the plasma levels below those leading to toxicity in case of systemic treatment. Besides that, it is not associated with local side effects [5, 14, 22]. Although the long term adverse effects of the intra-lesional administration of cidofovir are not well-known, theories mentioned that a risk of malignant transformation may be associated with its use [4, 22].

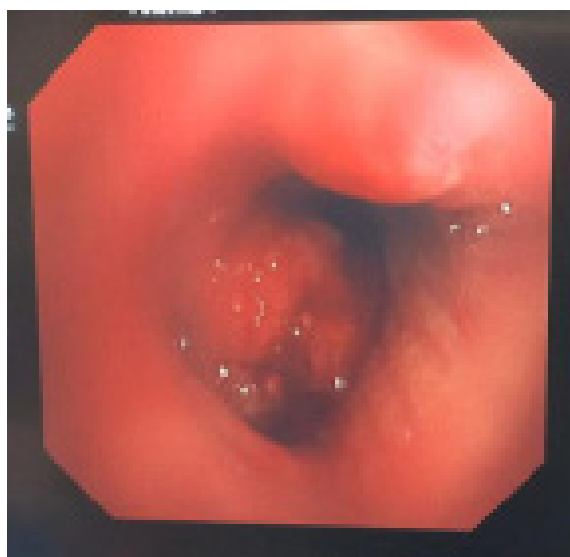Vaccination against HPV offers potential for the future eradication of the disease through reduction of the incidence and the transmission of the virus. The quadrivalent vaccine is given for the prevention of cervical, ano-genital cancers, and pre-carcinogenetic lesions that are associated with HPV subtypes 6, 11, 16, and 18 [28]. The vaccine carries a promise for patients affected by respiratory papillomatosis. However, multicenter trials should validate the isolated positive experiences which may determine the true benefits of the vaccination as a treatment for respiratory papillomatosis [5].

## CASE PRESENTATION

We present here a 35 years old male patient who was referred to our department complaining of left sided pleuritic chest pain and chronic non-productive cough. The symptoms dated one month prior to the presentation and increasing in the severity. Patient had neither hemoptysis nor loss of weight and there were no other symptoms. Patient had a history of seasonal bronchial asthma and history of pigtail catheter insertion for left sided pleural effusion two years earlier of undetermined nature. Moreover, the patient has a positive family history for breast cancer (three aunts) and questionable family history of lung cancer.

The CXR on admission; revealed a partial atelectasis-consolidation of the left upper lobe while the CT-Chest on April 2017, showed left endo-bronchial lesion located at the left main bronchus measuring (7.5X12.5 mm) that was associated with an enlarged left hilar LN causing obstructive consolidation (Fig. 1). PET-CT scan was performed on May 2017. It showed suspicious metabolically active nodule located inside the left main bronchus. V-Q scan Rt 73.9% and Lt 26.1%. Fibre-optic bronchoscopy was performed showed a left main bronchial mass occluding the left upper lobe. Biopsy was taken directly from the mass. Histo-pathological examination

revealed a multiple mixed glandular and squamous cell papilloma. Although the pathologist considered the differential diagnosis of inflammatory polyps, he favored the diagnosis of multifocal papillomatosis due to the presence of squamous epithelial hyperplasia and glandular epithelium. The surgical resection or ablation was the treatment of choice to restore the patency of the airway and to eradicate the disease. Two options of surgical interventions were proposed. The first option was the thermal ablation of the mass lesion via combined rigid and fibre-optic bronchoscopy. The second option was to perform a sleeve left upper lobectomy. Following discussion with the patient, the first option was favored by the patient and the treating medical team. The second surgical option was postponed if the first one was unsuccessful or incomplete.



**Figure 1.** CT-Chest (mediastinal window) of the patient with respiratory papilloma showing a endo-luminal mass located at the left main bronchus and encroaching on the left upper lobe bronchus

Patient had general anesthesia and rigid bronchoscopy was performed. Right side was reevaluated carefully again with the use of 0.5 mm 30 degrees telescope and proved to be healthy and harboring no lesions. Then the left side was evaluated. A sessile large lesion was found located within the left main bronchus and partially obstructing the left main bronchus and left upper lobar bronchus. It was extending up to the carina and just 1.5 cm away from it. The rigid bronchoscope was unable to pass the lesion. Hence, the fibre-optic bronchoscope was delivered through the lumen of the rigid bronchoscopy and passed the lesion to evaluate the trachea-bronchial tree distally. No other lesions were found beyond this large papilloma.

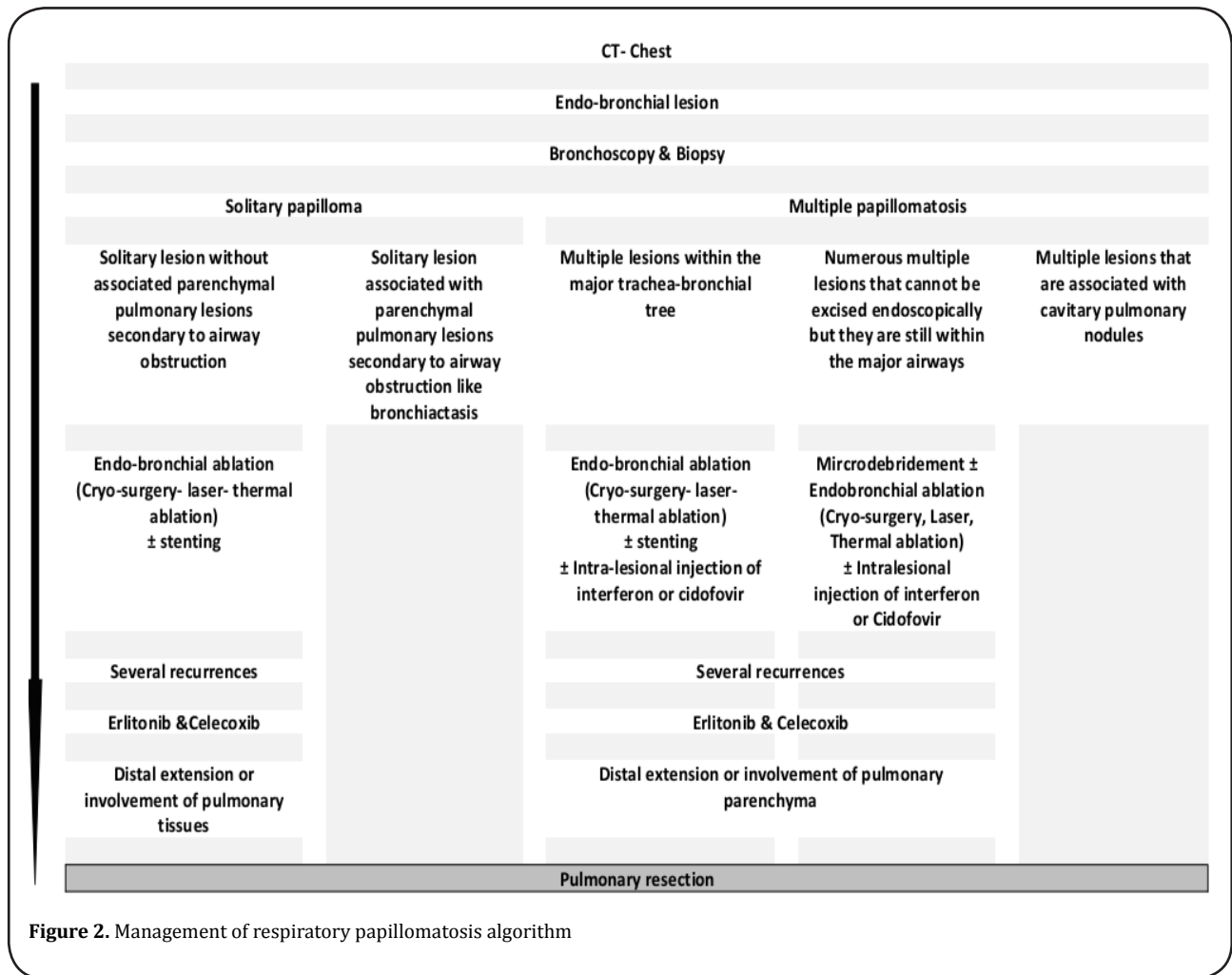
Then the fibre-optic bronchoscopy was pulled up to rest above the proximal end of the lesion. A diathermy ablation probe was introduced and thermal ablation of the lesion was taken place starting from the distal end of the lesion at the base. Then, part of the lesion was thermally snared. The lesion was then completely removed by biopsy forceps. The

base was thermally ablated completely. A tracheo-bronchial lavage was performed. Then both, the fibre-optic and rigid bronchoscopes, were removed. Endo-tracheal tube was introduced. Patient was extubated at the operating room. No intra-operative complications were encountered. The excised lesion was sent for histo-pathological examination.

The histo-pathological examination of the specimen sent revealed a bronchial papilloma with mixed fungal infection (actinomycosis and aspergillosis). Patient was discharged on medical treatment for actinomycosis and aspergillosis. Follow-up visits were planned following one month and then every three months. Patient is doing well on follow-up with no new complaints.

## DISCUSSION

Squamous papillomas are rare tumors. They usually accounted for not more than 8 % of all benign pulmonary tumors<sup>[29]</sup>. The majority of publications found in the literature are case reports. They included one or two patients<sup>[13,29-34]</sup>. Other publications are small series of patients and included between six and nine patients like those published by Lang et al.<sup>[1]</sup> and Ablanedo-Terrazas et al.<sup>[35]</sup>. It is infrequently to be asymptomatic and discovered incidentally on radiological examination. However, the majority of patients are symptomatic. Symptoms are variable. They include wheezes, cough, hemoptysis, or recurrent pneumonia. In our patient, the main complaint was chronic cough non responding to treatment. Usually, symptoms are secondary to the mass obstructive effects within the airways<sup>[4,29]</sup>. As respiratory papilloma usually presents as an endo-bronchial lesion, it usually leads to bronchial stenosis with subsequent atelectasis that predisposes to recurrent infection and pneumonia and finally ends with bronchiectasis<sup>[29]</sup>. Our patient was male at the middle age and the squamous papillomas are more common to occur in men<sup>[1,13,29-31,36]</sup>. Squamous papillomas have a potential of malignant transformation in up to 40 % of cases. Furthermore, the incidence of occurrence of malignancy elsewhere in the lung is around 13 %<sup>[29,37]</sup>. Hence, careful endoscopic examination of the tracheo-bronchial tree with good biopsy specimens is essential for those patients. Pathologist should be meticulous during examinations of these tissues both during first diagnosis and after complete excision. The methods of treatment; either endoscopic removal or surgical resection; are still controversial. Endoscopic ablation by laser or diathermy may prevent a full pathological examination of the whole papilloma, which may harbor a carcinoma<sup>[29]</sup>. Therefore, it is recommended to completely excise the solitary squamous papilloma in order to exclude an invasive malignancy and prevent recurrence<sup>[38]</sup>. In our patient, we passed the bronchoscope first beyond the lesion to evaluate the extent the lesion and then thermal ablation was applied at the periphery of the lesion and the base to completely excise the mass with preservation of tissues for histo-pathological examination to exclude malignancy or malignant transformation. The surgical resection should be deferred as the last option and when considered the surgeon should perform lung-sparing surgical techniques as sleeve lobectomy or bronchoplasty instead of extensive resection as these are benign lesions. Extensive pulmonary resection is considered only in case of extension of the



disease to the pulmonary parenchyma or in patients who had a complicated disease with bronchiectasis<sup>[13, 29, 30]</sup>. The majority of authors recommended endo-bronchial surgical excision using laser, cryo-surgery or thermal ablation or intra-lesional injection of anti-viral drugs instead of resection<sup>[13, 31, 34, 35, 36]</sup>. We preferred thermal ablation for the lesion in our patient. No complications were encountered intra-operatively. The final histo-pathology revealed a complicated squamous respiratory papilloma with superadded infection by aspergilliosis and actinomycosis. Few cases are reported like this case in the literature especially in immune-competent patients<sup>[39, 40]</sup>. However, those patients reported in the literature had recurrent respiratory papillomas not like our patient who had it for the first time. The patient had treatment for the infection associated and instructed for close follow-up. As this disease is rare and treatment is non-standardized, our group of research has proposed an algorithm for its management based on the revision of the literature (Fig. 2). This algorithm firstly classifies the lesion either multiple or solitary and then goes forward according to the absence or presence of complications and the involvement of pulmonary parenchyma. Furthermore, it takes into consideration the recurrence of the disease and its progression during the course of its management.

## CONCLUSION

In conclusion, respiratory papillomas are rare benign lesions. They are characterized by the appearance of papillomatous lesions anywhere in the tracheo-bronchial tree. It affects children and young adults. Although the disease affects mainly the upper airways, it may be aggressive and extends distally to the lower respiratory tract and pulmonary parenchyma. The course of the disease is unpredictable. It may regress spontaneously, but in other instances it may lead to serious complications ranging from airway obstruction up to malignant transformation. Endo-bronchial interventions and surgical excision are the mainstay of definitive treatment to prevent recurrence and to exclude malignancy.

### Ethical approval and consent to participate

Ethical approval has been exempted by faculty ethical committee based on absence of any risk or violation of applied guidelines in such cases.

### Conflicts of interest

None-declared.

## REFERENCES

- Lang, T. U., Khalbuss, W. E., Monaco, S. E., & Pantanowitz,

- L. (2011). Solitary Tracheobronchial Papilloma: Cytomorphology and ancillary studies with histologic correlation. *Cytojournal*, 8.
2. Travis, W. D., Brambilla, E., Muller-Hermelink, H. K., & Harris, C. C. (2004). World Health Organization classification of tumours. Pathology and genetics of tumours of the lung, pleura, thymus and heart, 10, 179-84.
  3. Wick, M. R., & Mills, S. E. (2018). Benign and borderline tumors of the lungs and pleura. In *Practical Pulmonary Pathology: A Diagnostic Approach* (pp. 665-722). Elsevier.
  4. Fortes, H. R., Von Ranke, F. M., Escuissato, D. L., Araujo Neto, C. A., Zanetti, Gláucia, & Hochegger, B., et al. (2017). Recurrent respiratory papillomatosis: a state-of-the-art review. *Respiratory Medicine*, 126, 116-121.
  5. Carifi, M., Napolitano, D., Morandi, M., & Dall'Olio, D. (2015). Recurrent respiratory papillomatosis: current and future perspectives. *Therapeutics and Clinical Risk Management*, 11(default), 731-738.
  6. Fusconi, M., Grasso, M., Greco, A., Gallo, A., Campo, F., Remacle, M., ... & De Vincentiis, M. (2014). Recurrent respiratory papillomatosis by HPV: review of the literature and update on the use of cidofovir. *Acta Otorhinolaryngologica Italica*, 34(6), 375.
  7. Marchiori, E., Araujo Neto, C. D., Meirelles, G. S. P., Irion, K. L., Zanetti, G., Missrie, I., & Sato, J. (2008). Laryngotracheobronchial papillomatosis: findings on computed tomography scans of the chest. *Jornal Brasileiro de Pneumologia*, 34(12), 1084-1089.
  8. Chang, C. H., Wang, H. C., Wu, M. T., & Lu, J. Y. (2006). Virtual bronchoscopy for diagnosis of recurrent respiratory papillomatosis. *Journal of the Formosan Medical Association*, 105(6), 508-511.
  9. Ağgünlü, L., & Erbaş, G. (2009). Recurrent respiratory papillomatosis with lung involvement. *Diagn Interv Radiol*, 15(2), 93-5.
  10. Venkatesan, N. N., Pine, H. S., & Underbrink, M. P. (2012). Recurrent respiratory papillomatosis. *Otolaryngologic Clinics of North America*, 45(3), 671-694.
  11. Goon, P., Sonnex, C., Jani, P., Stanley, M., & Sudhoff, H. (2008). Recurrent respiratory papillomatosis: an overview of current thinking and treatment. *European Archives of Oto-Rhino-Laryngology*, 265(2), 147-151.
  12. Donne, A. J., Hampson, L., Homer, J. J., & Hampson, I. N. (2010). The role of HPV type in recurrent respiratory papillomatosis. *International Journal of Pediatric Otorhinolaryngology*, 74(1), 7-14.
  13. Katsenos, S., & Becker, H. D. (2011). Recurrent respiratory papillomatosis: a rare chronic disease, difficult to treat, with potential to lung cancer transformation: apropos of two cases and a brief literature review. *Case reports in oncology*, 4(1), 162-171.
  14. Gelinas, J. F., Manoukian, J., & Côté, A. (2008). Lung involvement in juvenile onset recurrent respiratory papillomatosis: a systematic review of the literature. *International journal of pediatric otorhinolaryngology*, 72(4), 433-452.
  15. Wiatrak, & Brian, J. (2003). Overview of recurrent respiratory papillomatosis. *Current Opinion in Otolaryngology & Head and Neck Surgery*, 11(6), 433-441.
  16. Reeves, W. C., Ruparelia, S. S., Swanson, K. I., Derkay, C. S., Marcus, A., & Unger, E. R. (2003). National registry for juvenile-onset recurrent respiratory papillomatosis. *Archives of Otolaryngology-Head & Neck Surgery*, 129(9), 976.
  17. Martina, D., Kurniawan, A., & Pitoyo, C. W. (2014). Pulmonary papillomatosis: a rare case of recurrent respiratory papillomatosis presenting with multiple nodular and cavitary lesions. *Acta Med Indones*, 46(3), 238-243.
  18. Lee, J. H., & Smith, R. J. (2005). Recurrent respiratory papillomatosis: pathogenesis to treatment. *Curr Opin Otolaryngol Head Neck Surg*, 13(6), 354-359.
  19. Prince, J. S., Duhamel, D. R., Levin, D. L., Harrell, J. H., & Friedman, P. J. (2002). Nonneoplastic lesions of the tracheobronchial wall: radiologic findings with bronchoscopic correlation. *Radiographics*, 22 Spec No(4), S215.
  20. Taliercio, S., Cespedes, M., Born, H., Ruiz, R., & Branski, R. C. (2014). Adult-onset recurrent respiratory papillomatosis a review of disease pathogenesis and implications for patient counseling. *JAMA Otolaryngology - Head and Neck Surgery*, 141(1), 78-83.
  21. Shiau, E. L., Li, M. F., Hsu, J. H., & Wu, M. T. (2014). Recurrent respiratory papillomatosis with lung involvement and malignant transformation. *Thorax*, 69(3), 302-303.
  22. Tasca, R. A., & Clarke, R. W. (2006). Recurrent respiratory papillomatosis. *Archives of Disease in Childhood*, 91(8), 689-691.
  23. Marchiori, E., Pozes, A. S., Souza Junior, A. S., Escuissato, D. L., Irion, K. L., & Cd, A. N., et al. (2008). [diffuse abnormalities of the trachea: computed tomography findings]. *Jornal Brasileiro De Pneumologia*, 34(1), 47-54.
  24. Xiao, Y., Wang, J., Han, D., Ma, L., & Lopez, F. A. (2015). A case of the intrapulmonary spread of recurrent respiratory papillomatosis with malignant transformation. *The American journal of the medical sciences*, 350(1), 55-57.
  25. Mauz, P. S., Zago, M., Kurth, R., Pawlita, M., Holderried, M., Thiericke, J., ... & Iftner, T. (2014). A case of recurrent respiratory papillomatosis with malignant transformation, HPV11 DNAemia, high L1 antibody titre and a fatal papillary endocardial lesion. *Virology journal*, 11(1), 114.
  26. Yu, J. P., Barajas, J. R., Olorunsola, D., Sugrue, L. P., & Hernandez-Pampaloni, M. (2013). Heterogeneous 18F-FDG uptake in recurrent respiratory papillomatosis. *Clinical nuclear medicine*, 38(5), 387-389.
  27. Dyrstad, S. W., & Rao, K. A. (2008). Recurrent respiratory papillomatosis (rrp)—juvenile onset. *Clinical Medicine: Oncology*, 2, 481-486.



28. Wilcox, L. J., Hull, B. P., Baldassari, C. M., & Derkay, C. S. (2014). Diagnosis and management of recurrent respiratory papillomatosis. *The Pediatric infectious disease journal*, 33(12), 1283-1284.
29. Lee, Y. O., Kim, D. H., Kim, C. H., Park, T. I., & Cho, S. (2009). Rare tumor of the tracheobronchial tree: solitary squamous papilloma. *The Thoracic and cardiovascular surgeon*, 57(03), 178-179.
30. Inamura, K., Kumasaka, T., Furuta, R., Shimada, K., Hiyama, N., Furuhashi, Y., ... & Takemura, T. (2011). Mixed squamous cell and glandular papilloma of the lung: a case study and literature review. *Pathology international*, 61(4), 252-258.
31. Limsukon, A., Susanto, I., Hoo, G. W. S., Dubinett, S. M., & Batra, R. K. (2009). Regression of recurrent respiratory papillomatosis with celecoxib and erlotinib combination therapy. *Chest*, 136(3), 924-926.
32. Marchiori, E., Zanetti, G., & Mauro Mano, C. (2010). Tracheobronchial papillomatosis with diffuse cavitary lung lesions. *Pediatric radiology*, 40(7), 1301-1302.
33. Grunzke, M. L., & Garrington, T. (2010). Diffuse cavitary lung lesions: reply to marchiori et al. *Pediatric Radiology*, 40(7), 1303-1303.
34. Mohan, K. T., Greenheck, J., & Rubio, E. R. (2008). Recurring tracheal papillomatosis treated with cryosurgery. *Southern medical journal*, 101(9), 967-968.
35. Ablanedo-Terrazas, Y., Soda-Merhy, A., M Hernández-Palestina, Ormsby, C. E., & G Reyes-Terán. (2012). Intralesional cidofovir in severe juvenile respiratory papillomatosis. *B-ENT*, 8(3), 197-202.
36. Bondaryev, A., Makris, D., Breen, D. P., & Dutau, H.. (2009). Airway stenting for severe endobronchial papillomatosis. *Respiration*, 77(4), 455-458.
37. Inoue, Y., Oka, M., Ishii, H., Kimino, K., Kishikawa, M., & Ito, M., et al. (2001). A solitary bronchial papilloma with malignant changes. *Internal Medicine*, 40(1), 56-60.
38. Litzky, & Leslie. (2003). Epithelial and soft tissue tumors of the tracheobronchial tree. *Chest Surgery Clinics of North America*, 13(1), 1-40.
39. Robb, P. K., Weinberger, P. M., Perakis, H., Li, A., Klein, A. M., & Johns, M. M., et al. (2011). Association of asthma with clinically aggressive recurrent respiratory papillomatosis. *Archives of Otolaryngology-Head & Neck Surgery*, 137(4), 368-372.
40. Kuruvilla, S., Saldanha, R., & Joseph, L. D. (2008). Recurrent respiratory papillomatosis complicated by aspergillosis: a case report with review of literature. *Journal of Postgraduate Medicine*, 54(1), 32-34.