

Abstract

Anatomical variations of gallbladder are a rare entity and duplication is one of the variants with two funds of gallbladder communication through a common channel cystic duct to the bile duct. Incidence of Gallbladder duplication has been reported 1:4000 in the literature. We report a case of incidental finding of gall bladder duplication during laparoscopic cholecystectomy for symptomatic cholelithiasis with both the funds harbouring gallstones with a single cystic duct and two cystic arteries. Surgery was successful with both gallbladders removed and no post operative complication reported. This case emphasises the need for removal of both the gallbladders in the same setting with recognition of possible vascular and biliary aberrant anatomy to avoid and complication during surgery.

Keywords : Duplicated gallbladder, Aberrant biliary anatomy, fundus duplication, laparoscopic cholecystectomy

Introduction

Aberrant anatomy of biliary structures like duplication of gallbladder is one of the rare presentations occurring in 1:3800-4000 births^[1]. These congenital anomalies pose a definite risk of biliary injury during operative interventions like laparoscopic cholecystectomy. Precise diagnosis pre-operatively is required for precise plan of management and to make sure both the gallbladders are removed completely without complications. As these anomalies are frequently associated with stone formation due to inadequate bile drainage. Laparoscopic cholecystectomy is the treatment of choice.

Case report

We report a case of incidentally finding of duplicated gallbladder during intraoperative procedure of laparoscopic cholecystectomy for symptomatic cholelithiasis in a 38yr lady. She presented to the OPD with complaints of recurrent pain in the right upper quadrant region for 4 months with fatty meal intake. Her medical history was not contributory and no history of any interventions in the past. Clinically her abdomen was soft, no tenderness or distention with no palpable lumps and no signs of jaundice. Her blood workup was normal and USG revealed a large distended gallbladder with multiple calculi and sludge with no signs of cholecystitis. Patient was taken up for laparoscopic cholecystectomy after taking proper informed consent. After introduction of scope we noticed an unusually large gallbladder upon exploration duplication of fundus of gallbladder was evident opening through a common channel cystic duct as shown in Figure 2. During Calot's dissection two cystic arteries were encountered and were carefully clipped and divided. The common cystic duct was clipped and divided and gallbladder extracted with no complications. Patient recovered well and was discharged the next day and she was followed further and no complications were reported.

Discussion

Incidence

Congenital variation of anatomy of gallbladder are rare. Duplication of gallbladder is one such variant occurring in 1 of every 3800-4000 births.^[1] It is thought to be due to exuberant budding of the developing biliary tree during the division of caudal bud of hepatic diverticulum. The first reported human case was noted in a sacrificial victim of Emperor Augustus in 31 BC. It is important to know because of the frequent association of cystic duct and artery variations^{[2][3][4]}.




Figure 1 : Boyden's classification congenital duplication of gallbladder

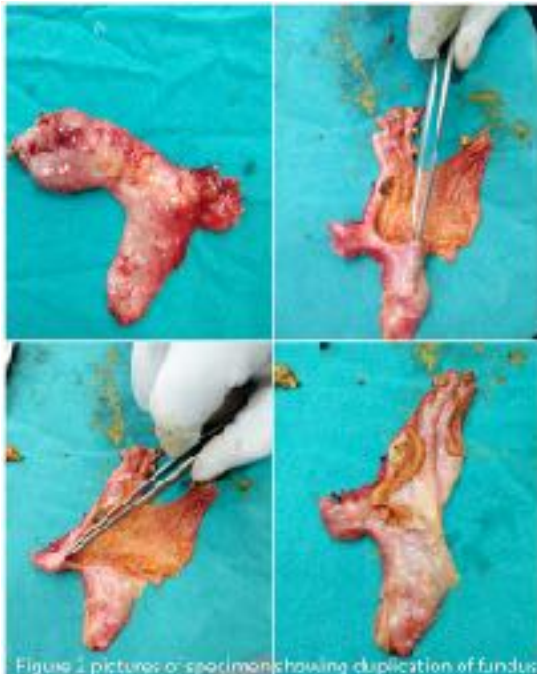

Figure 2 pictures of specimen showing duplication of fundus

Etiology

According to Boyden's classification in Figure : 1

- (1) Vesica fellea divisa (bilobed or bifid gallbladder, double gallbladder with a common neck),
- (2) Vesica fellea duplex (double gallbladder with two cystic ducts),
 - (i) Y-shaped type (the two cystic ducts uniting before entering the common bile duct),
 - (ii) H-shaped type (ductular type, the two cystic ducts entering separately into the biliary tree).

Of these vesica fellea duplex is true duplication and is more common. The anatomical location may vary but share a common peritoneal coat

and are usually beside each other or one could be entirely intrahepatic or subhepatic. True gall bladder duplications may share a common cystic duct, arterial supply or have separate cystic ducts and blood supply.^{[5][6]}

Clinical features

Duplicated gallbladder is a rare anomaly that cannot be accurately assessed, since the only cases which have been identified are those that became symptomatic or were encountered as incidental findings during surgery, imaging studies or at autopsy. Usually present with similar complaints as with normal gallbladder disease and as there is no significant risk for subsequent disease, prophylactic cholecystectomy in an asymptomatic patient with gallbladder duplication is not recommended.

Diagnosis

Gallbladder duplication can be detected preoperatively by imaging studies. USG is generally the first choice of imaging modality in patients with suspected biliary disease. USG may diagnose gallbladder duplication if the viscera are located separately may suggest a double gallbladder, the cystic duct is usually not identified and it is often impossible, as in our case, to distinguish bilobed gallbladder from a distended gallbladder. MRI or a CECT would be more valuable in visualising duplicated gallbladder preoperatively.^{[7][8]}

Management

Laparoscopic cholecystectomy would be advised for patients with symptomatic cholelithiasis with preoperatively detached duplicated gallbladder with no evidence for intervention in asymptomatic incidentally discovered duplicated gallbladder.

Conclusion

Duplication of gallbladder is a rare congenital anomaly which requires attention as it is often associated with other aberrant anatomy cystic duct hepatic and cystic artery. Careful delineation of anatomy preoperative or intraoperatively may be required in such cases.

References

1. E. A. Boyden, "The accessory gallbladder: an embryological and comparative study of aberrant biliary vesicles occurring in man and the domestic mammals," *American Journal of Anatomy*, vol. 38, pp. 177–231, 1926.
2. R. Udelsman and P. H. Sugarbaker, "Congenital duplication of the gallbladder associated with an anomalous right hepatic artery," *American Journal of Surgery*, vol. 149, no. 6, pp. 812–815, 1985.
3. M. Lamah, N. D. Karanjia, and G. H. Dickson, "Anatomical variations of the extrahepatic biliary tree: review of the world literature," *Clinical Anatomy*, vol. 14, no. 3, pp. 167–172, 2001.
4. P. R. Kothari, T. Kumar, A. Jiwane, S. Paul, R. Kutumbale, and B. Kulkarni, "Unusual features of gall bladder duplication cyst with review of the literature," *Pediatric Surgery International*, vol. 21, no. 7, pp. 552–554, 2005.
5. Horattas MC. Gallbladder duplication and laparoscopic management. *J Laparoendosc Adv Surg Tech A* 1998;8:231-5.
6. Miyajima N, Yamakawa T, Varma A, Uno K, Ohtaki S, Kano N. Experience with laparoscopic double gallbladder removal. *Surg Endosc* 1995; 9:63-6
7. A. Ozgen, D. Akata, A. Arat, F. B. Demirkazik, M. N. Ozmen, and O. Akhan, "Gallbladder duplication: imaging findings and differential considerations," *Abdominal Imaging*, vol. 24, no. 3, pp. 285–288, 1999.
8. S. Mazziotti, F. Minutoli, A. Blandino, S. Vinci, I. Salamone, and M. Gaeta, "Gallbladder duplication: MR cholangiography demonstration," *Abdominal Imaging*, vol. 26, no. 3, pp. 287–289, 2001.

