

Research article

Preoperative predictive factors of liver hydatid cyst occult or frank intrabiliary rupture

Mohamed Wejih Dougaz^a, Mohamed Ali Chaouch^{a*}, Houcine Magherbi^b, Mehdi Khalfallah^a, Hichem Jerraya^a, Ibtissem Bouasker^a, Ramzi Nouira^a, Chadli Dziri^a

^aDepartment B of Surgery, Charles Nicolle Hospital, Tunis, Tunisia.

^bDepartment A of surgery, Rabta Hospital, Tunis, Tunisia.

Abstract

Background: The most frequent complication of liver hydatid cyst is intrabiliary rupture (LHCIBR). This study aimed to investigate preoperative predictive factors of occult and frank LHCIBR.

Methods: We conducted a retrospective study concerning patients operated on consecutively for liver hydatidosis for 2 years. Patients were divided into three groups: who had no intrabiliary rupture, patients who had an occult rupture and patients who had a frank rupture.

Results: We recorded 56 patients with 82 liver hydatid cysts. LHCIBR was occult in 16 cysts and frank in four cysts. Bivariate analysis identified jaundice and cyst size as associated with frank LHCIBR and US cyst type II or III, recurrent cyst, and size of the hydatid cyst as associated with occult LHCIBR. In the multivariate analysis, we retained jaundice, cyst size > 6.5 cm and duration of symptoms > 45 days as significant predictive factors of frank rupture and cyst size > 6.5 cm, number of recurrences ≥ 3 , cyst type II or III, leukocytosis > 9.000/mm³ and eosinophilia > 5.5% as significant of occult rupture.

Conclusion: Misdiagnosis LHCIBR can lead to increased morbidity and mortality. They were avoided by predicting cyst rupture, correct timing and type surgery, proper drainage and preoperative intensive care of patients.

Keywords: Liver hydatid cyst; Occult intra-biliary rupture; Frank intra-biliary rupture; complication; predictive factors

INTRODUCTION

Hydatid cyst is a worldwide zoonosis caused by *Echinococcus granulosus* [1]. The source of infection is equivocal, but it is most likely from *E. granulosus* eggs passed in the feces of wild dogs [2]. This parasitic disease could affect any organs [3,4]. It affects essentially the liver. This is due to vascular specificities of this organ. Parasitic evolution could be marked by several complications. The most frequent complication of liver hydatid cyst is intrabiliary rupture [5,6]. It presents the cornerstone of hydatid disease evolution and it may lead to acute cholangitis owing to obstruction of the biliary tree, with an increase of morbidity and mortality rate to 50% [5,7]. Early diagnosis and treatment of these complicated cysts are mandatory. This complication can be suggested preoperatively regarding clinical, biological or radiological findings or

discovered during surgery and can even be declared in the postoperative delay by a biliary leakage. Prediction of intrabiliary liver hydatid cyst rupture is important for early diagnosis, proper management, and proper choice of the surgical approach and type of surgery. This study aimed to investigate preoperative predictive factors of occult and frank intrabiliary rupture of liver hydatid cyst.

METHODS

We conducted a retrospective study concerning patients operated on consecutively for liver hydatidosis for two years. Diagnosis of liver hydatid cyst was confirmed by ultrasound, CT-scan and hydatid cyst serology test (ELISA, arc 5). We used the hospital archive for the study. Preoperative demographic, clinical, biological and imaging findings characteristics were recorded. Patients who had a past medical history of jaundice or high level of total bilirubin value that was due to another affection then liver hydatid cysts were excluded from the study. All patients underwent liver function tests (Total bilirubin level, gamma-glutamyl-transpeptidase (GGT), Aspartate aminotransferase and alkaline phosphatase level) and hematologic studies (leukocytosis, eosinophilia). The lo-

*Corresponding author: Mohamed Ali Chaouch

Mailing address: Department B of Surgery, Charles Nicolle Hospital, Tunis, Tunisia.

Email: Docmedalichaouch@gmail.com

Received: 15 September 2019 Accepted: 25 September 2019

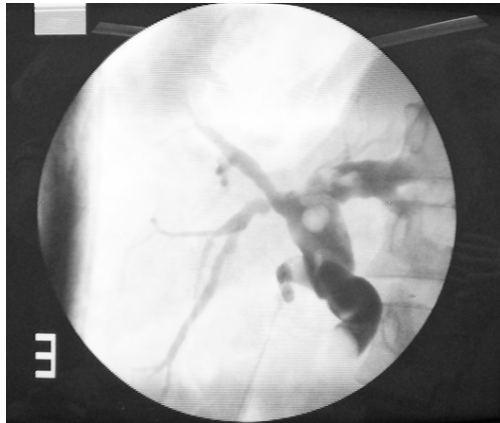


Figure 1. Intra-operative cholangiogram showing a dilated biliary tract with a filling defect in the common bile duct due to the presence of a hydatid daughter cyst.

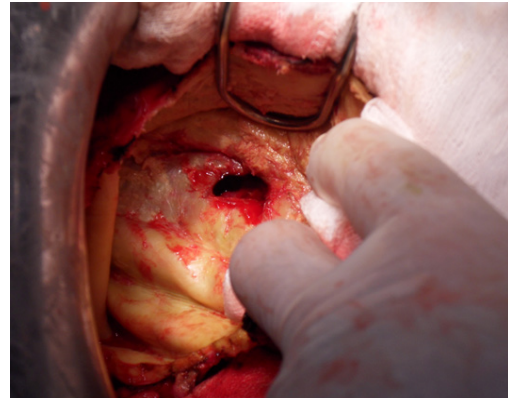

Figure 2. Intra-operative picture showing a large liver hydatid cyst wall in case of a frank rupture.

cation of all hydatid cysts was determined by preoperative ultrasound, computed tomography and confirmed by surgical findings. Cysts were classified preoperatively according to ultrasound Gharbi classification [8] and intraoperatively by Couinaud's segments of the liver [8]. No medical treatment (Albendazole) was used before surgery. Only surgical management was adopted. Conservative procedures were performed for all patients. The area around the cyst was protected and covered with packs immersed in hypertonic saline serum. This precaution was performed to decrease the risk of parasite spread during cyst evacuation. The cyst was incised at its protruded part. The cyst was widely opened by excising the protruded part of the pericyst. The cyst content was aspirated and germinative membrane was removed using forceps. The pericyst was smoothed out and cleaned to remove even non-apparent daughter cysts in the pericyst. The residual cavity was examined to look for intrabiliary rupture. A cholecystectomy and a cholangiogram were performed when communication between the hydatid cyst and the biliary tract or a common bile dilation were found (Figure 1). Biliary communication was sutured when they were < 5 mm and treated by directed fistulation when it was larger than 5 mm. If the hydatid fluid was bile stained, with no evidence of biliary communication, the residual cavity was aspirated using external drainage. An omentoplasty was performed systematically to treat remained cavity. Regarding intraoperative findings, patients were divided into three groups: patients who had no intrabiliary rupture, patients who had an occult rupture and patients who had a frank rupture. An occult rupture was defined as the presence of bile in the cyst without passage of intracystic content into the common bile duct. A frank rupture (Figure 2) was defined as a passage of the intra-

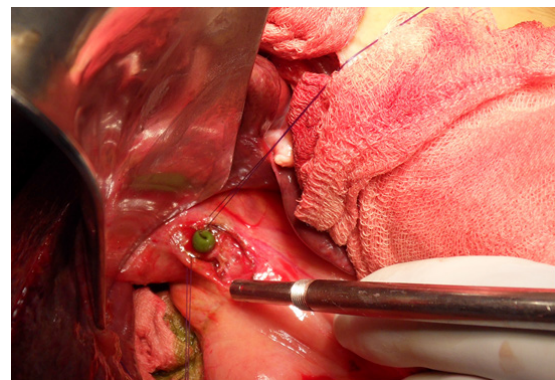


Figure 3. Intra-operative picture showing hydatid cyst membrane in the common bile duct after choledocolotomy.

cystic content into the biliary tree (Figure 3) with a large bilio-cystic fistula (diameter larger than 5 mm). Collected data were analyzed using the SPSS (v.23). Continuous variables were presented by the mean \pm standard deviation and qualitative variables by percentage. For comparison between the three groups, we used the Student t-test and Mann-Whitney test for continuous variables when appropriate; the chi-square test and Fisher exact test for categorical variables. A p-value of less than 0.05 was considered significant. Receiver operating characteristic (ROC) curve was used to evaluate the optimal cut-off values. The sensitivity, specificity, likelihood ratio, and positive and negative predictive values were calculated to identify predictive factors of occult and frank rupture in biliary tract of liver hydatid cyst.

RESULTS

Descriptive study

Our study recorded 56 patients with 82 liver hydatid

Table 1. Demographic, clinical, biological and radiological characteristics of patients.

Variables	N (%) / Median (ranges) / Mean (\pm SD)
Demographic data	
Median duration of symptoms in months	2 [1-16]
Age (year)	49 \pm 19
Gender	
Women	43 (77%)
Men	13 (23%)
Clinical presentation	
Right upper quadrant abdominal pain	44 (97%)
Asymptomatic	
Symptomatic	
History of jaundice	4 (7%)
Nausea and vomiting	6 (11%)
Duration of symptoms (days)	180 [1-1440]
Abdominal mass	5 (9%)
Jaundice	4 (7%)
Fever	7 (13%)
Biological tests levels	
Total bilirubin level (μ mol/l)	14 [3.9 - 244.3]
BC	20 [2 - 175]
Alkaline phosphatase level (U/l)	94.5 [39 - 369]
GGT level	63 [11 - 506]
ALP level	101 [39 - 369]
Leukocytosis ($10^3/mm^3$)	6850 [2300 - 23200]
Eosinophilia ($10^3/mm^3$)	2900 [100 - 15200]
C-reactive protein	46 [3.9 - 101]
Biliary duct dilation	
Yes	8 (9%)
No	71 (86.5%)
Cyst Size (cm)	7.5 [1-17]
Number of cysts	
Unique cyst	32 (57%)
Multiple cysts	24 (43)
Recurrent cyst	15 (27%)
Cyst location	
Right liver	64 (78%)
Left liver	13 (16%)
Both lobe	5 (6%)
Gharbi's classification	
I	18 (22%)
II	6 (7%)
III	43 (52%)
IV	14 (17%)
V	1(1%)
Cyst wall (pericyst)	
Soft	35 (42.6%)
Fibrotic or calcified	4 (4.8%)
Non-mentioned	43 (52.4%)
Intra-biliary hydatid rupture	
Frank	4 (4,87%)
Occult	16 (19,51%)

cysts. There were 13 men (23%) and 43 women (77%) with a mean age of 49 ± 19 years. The most common symptom was right upper quadrant abdominal pain in 44 patients (79%). A history of jaundice was found in four patients (7%) and seven patients (12%) were asymptomatic. The duration of symptoms ranged from one day to four years (median, 180 days). Abdominal examination objectified an abdominal mass in five patients (9%). The disease was primary in 41 patients (73%) and recurrent in 15 patients (27%). An abdominal ultrasound was performed systematically and CT-scan in 49 patients (87,5%). The majority of patients had a single cyst, there were in 32 patients (57%) and multiple cysts in 24 patients (43%). Associated extra-hepatic hydatid cysts were found in 10 patients (18%). Finally, we counted 82 liver hydatid cysts presented by 56 patients. Sixty-four cysts were located in the right liver lobe (78%), 13 cysts in the left liver lobe (16%) and five cysts were both lobe (6%). The cyst size ranged from 1 to 17 cm (median: 7.5 cm). Regarding ultrasonography Gharbi classification, among the 82 cysts, 18 cysts (22%) type I, 6 cysts (7%) were type II, 43 cysts (52%) were type III, 14 cysts (17%) were type IV and one cyst was type V. Imaging findings showed a dilation of common bile duct in 5 patients (8,9%). All surgical procedures were performed using an open approach and conservative treatment was adopted for all patients. Intrabiliary rupture was detected in 20 hydatid cysts (24,4%). It was an occult communication in 16 cysts (80%) and a frank intra-biliary rupture in four cysts (20%)(Table 1).

Analysis study

The bivariate analysis allowed us to identify the preoperative variables associated with frank intra-biliary hydatid rupture. There were significant statistically ($p < 0.05$) according to jaundice, and size of the cyst (Table 2). Concerning occult intrabiliary rupture, there were significant statistically ($p < 0.05$) according to ultrasonography Gharbi's classification type II or III cyst, recurrent cyst, and size of the hydatid cyst (Table 3).

As concern, the size of the cyst, ROC curve (Figure 4) was used to determine the most appropriate cut-off point which was 6.5 cm with a sensitivity of 83%, a specificity of 60% and a negative predictive value of 92%.

In the multivariate analysis we retained jaundice, cyst size > 6.5 cm and duration of symptoms > 45 days as significant predictive factors of frank rupture. Concerning occult rupture, we retained in the multivariate analysis cyst size > 6.5 cm, a number of recurrences ≥ 3 , cyst type II or III, leukocytosis $> 9.000/\text{mm}^3$ and eosinophilia $> 5.5\%$.

DISCUSSION

Our study investigates preoperative predictive factors of intrabiliary rupture of liver hydatid cyst in order to perform early diagnosis and management of this complication. Based on our findings, the preoperative variables associated with frank intra-biliary hydatid rupture were jaundice and cyst's size. Ultrasonography Gharbi's classification type II or III cyst, recurrent cyst and cyst's size were associated with occult intra biliary rupture. Multivariate analysis retained jaundice, cyst size > 6.5 cm and duration of symptoms > 45 days as predictive factors of frank rupture and cyst size > 6.5 cm, number of recurrences ≥ 3 , cyst type II or III, leukocytosis $> 9.000/\text{mm}^3$ and eosinophilia $> 5.5\%$ as predictive factors of occult rupture.

Intrabiliary hydatid cyst rupture is the most frequent complication of liver hydatid cysts^[6,10,11]. There is no consensus concerning the terminology of hydatid cyst with intrabiliary rupture^[5,12]. Its incidence depends largely

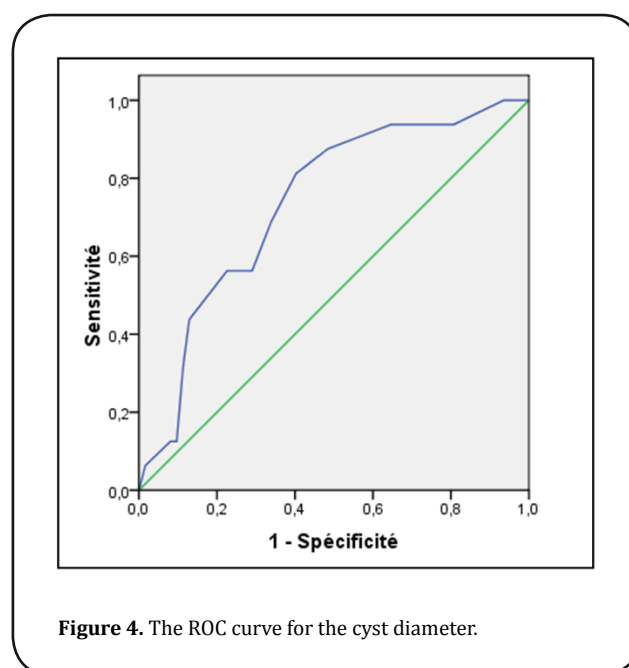


Figure 4. The ROC curve for the cyst diameter.

on the definition used to retain the occurrence of this rupture^[5]. In the literature, it was between 21 and 37%^[12,13]. Prediction of intrabiliary liver hydatid cyst rupture using clinical, biological and imaging factors is important for early diagnosis and proper management to enhance post-operative outcomes^[14]. It is commonly admitted that intrabiliary cyst rupture is related to higher morbidity and mortality rates^[5,12]. Intracystic pressure increases along with the diameter of a hydatid cyst and lead to a spontaneous intrabiliary rupture^[6]. This pressure causes intermittent passage of cyst fluid and minor fragments into the biliary system. However, an apparent biliary obstruction does not occur^[9]. A clear hydatid fluid without bile in the cyst cavity does not mean an intact

Table 2. Comparison between frank rupture or occult rupture versus no intrabiliary rupture of the liver hydatid cysts (bivariate analysis).

Variables	Intrabiliary rupture (n=20)		No rupture (n=62)	P	
	Frank rupture (n=4)	Occult rupture (n=16)		Frank rupture	Occult rupture
Age (year)	48 ± 17	45 ± 17	49 ± 19	0.925	0.488
Jaundice	2 (50%)	2 (1.25%)	3 (5%)	0.026	0.618
Abdominal mass	2 (50%)	1 (0.625%)	6 (10%)	0.069	0.681
Leukocytosis	10566 ± 3056	9156 ± 4518	7454 ± 3212	0.052	0.115
Size of cyst (cm)	11 ± 3	10 ± 3	5 ± 3	0.010	0.004
Type II or III	4 (100%)	15 (94%)	28 (45%)	0.050	< 0.001

cyst wall. Liver hydatid cyst intra biliary rupture is the major turning-point in the liver hydatid cyst evolution. It leads to cyst infection, cholangitis, sepsis, jaundice, pancreatitis, acute cholecystitis and liver abscesses [11,15,16]. Even late biliary cirrhosis could be reported [17]. In addition, when intrabiliary rupture was suspected, percutaneous drainage and the use of scolicalid agents should be avoided because of septic complications and the risk of sclerosing cholangitis [5]. Suitable treatment may avoid postoperative cystic cavity-related complications [5].

The cysto-biliary fistula may occur essentially in two forms: an occult rupture in 10% to 37% of cases or a frank rupture in 3% to 17% of cases [5,7,18]. In our study, the overall incidence of the cysto-biliary fistula was 24%. There was frank rupture in 4.87% and occult rupture in 19.51% of cysts.

The frank intrabiliary rupture is easily suggested pre-operatively. Careful past medical history, patient story, physical examination, and complementary exams predict this complication [19,20]. There was essentially obstructive jaundice, hyperbilirubinemia, gamma-glutamyl transferase or levels of alkaline transferase in the blood samples [19,21]. Even cholangitis can be observed in some cases [22]. CT-scan and ultrasound are useful diagnostic tools [23,24]. The presence of associated liver hydatid cyst, dilated biliary tract with cholangitis are strongly suggestive of frank intrabiliary rupture [25]. In the case of frank rupture, abdominal ultrasound had a sensitivity of 66,7% and a specificity of 100% [7]. Concerning abdominal CT-scan, it detects 75% of major cysts rupture [14]. Atli et al [7] reported suggestive ultrasound findings, type IV cysts and a cyst diameter larger than 10.5 cm as independent imaging predictive factors of frank rupture. Al-Bahrani et al [26] had investigated predictive factors of frank intrabiliary rupture in a study concerning 741 patients operated between 1965 and 2000. Multivariate analysis identified cyst size (≥ 10 cm), cyst infection, multivesicular content, solitary cysts and location in the left lobe of liver as well as long duration of symptoms as independent predictors of frank intrabiliary rupture [26].

Occult intrabiliary rupture of hydatid cyst is more frequent, asymptomatic and intraoperatively diagnosed [7,25]. It must keep in mind that these occult fistulas may give rise to a frank perforation at any time. Then early diagnose and management is important. These ruptures were defined as the presence of bile in the cyst without passage of intracystic content into the common bile duct. Thus, an apparent biliary obstruction does not occur. Different variables have been reported as risk factors for cysto-biliary fistula in the literature.

Atli et al [7], in a series of 116 patients, found that a history of nausea and vomiting, a serum ALP level greater than 144 UI/l, a total bilirubin level greater than 0,8 mg/dl, and cyst size greater than 14.5 cm were associated to occult intrabiliary cyst rupture.

Imaging features are not very helpful to detect occult intrabiliary cyst rupture [13]. Often this complication is discovered intra-operatively proved by bile in the hydatid cyst fluid [27]. Diagnosis is performed by the detection of a bilio-cystic fistula in the cyst wall during surgery or during intraoperative cholangiogram and even by ERCP performed before surgery [5]. Magnetic resonance cholangiography may become an effective diagnostic tool but now it is yet to be defined in the assessment of hydatid cyst intrabiliary rupture [28,29]. Among the different studies illustrated, cyst size seems to be the most important factor. In our study, hydatid cyst type II or III and cyst size above 6.5 cm were a predictive factor of cysto-biliary fistula. Atli [7] and Unalp [13] reported respectively a cyst diameter above 10.5 and 10 cm as predictive factors of occult intrabiliary cyst rupture with no relation between biliary leakage and nature of the cysts, whether primary or recurrent, single or multiple and their location (right lobe, left lobe or both).

This complication could affect the surgeon's choice regarding the surgical approach (Laparoscopy or laparotomy) [30] and the surgical procedure (conservative or radical treatment) [31].

Since cyst-biliary communication is a life-threatening condition, early diagnosis and treatment are mandatory. Surgeons should suspect a cysto-biliary communication

Table 3. Results of multivariate analysis of predictive factors.

Variables	OR	%95 CI	P
Frank cysto-biliary intrabiliary rupture			
Jaundice	19.7	2 – 191.8	0.026
Size > 6.5 cm	8.6	3 - 19	0.033
Duration of symptoms > 45 days	29.4	2.6 – 338.3	0.007
Occult cysto-biliary intrabiliary rupture			
Size > 6.5 cm	6.4	1.6 – 24.8	0.033
Number of recurrences ≥ 3	14	1.3 – 146.3	0.026
Type II or III	18.2	2.3 – 146.5	< 0.001
Leukocytosis > 9,000/mm ³	4.5	1.3 – 15.1	0.018
Eosinophilia > 5.5%	6.5	1.3 – 33	0.029

of a hydatid cyst if patient presents risk factors. In this situation, a broad-spectrum antibiotic should be chosen for prophylaxis and patients should be treated surgically as early as possible. In addition, suggesting intrabiliary rupture of the liver hydatid cyst can be useful in patient's selection to percutaneous treatment or laparoscopy [30,32,33]. Intraoperative cholangiography should be done systematically [6].

The limitation of this study is being a retrospective study. The character of peri cyst thick was evaluated by the surgeons with no standard definition attributed.

CONCLUSION

Misdiagnosis of intrabiliary rupture of hepatic hydatid cyst can lead to increasing postoperative cavity-related complications. Cysto-biliary communication should be suspected preoperatively and searched carefully intra-operatively in the presence of preoperative predictive factors. It could affect the surgeon's choice regarding the surgical approach (Laparoscopy or laparotomy) and the surgical procedure (conservative or radical treatment). In conclusion, decreasing morbidity and mortality were warranted by predicting intrabiliary cyst rupture, correct timing, and type of surgery, proper drainage and preoperative intensive care of patients.

CONFLICT OF INTEREST

Authors had no conflicts of interest to disclose.

REFERENCES

- Dziri, C., Haouet, K., Fingerhut, A., & Zaouche, A. (2009). Management of cystic echinococcosis complications and dissemination: where is the evidence?. *World journal of surgery*, 33(6), 1266-1273.
- Jenkins, D.J., Williams, T., Raidal, S., Gauci, C., & Lightowlers, M. W. (2019). The first report of hydatid disease (*Echinococcus granulosus*) in an Australian water buffalo (*Bubalus bubalis*). *International Journal for Parasitology: Parasites and Wildlife*, 8, 256-259.
- Dougaz, M. W., Chaouch, M. A., Derbel, B., Achouri, L., Bouasker, I., & Nouria, R. (2019). An unusual zoonotic parasite's disease causing a breast mass: Breast hydatid cyst. *International Journal of Infectious Diseases*.
- Dziri, C. (2001). Hydatid disease-continuing serious public health problem: introduction. *World journal of surgery*, 25(1), 1-3.
- Kayaalp, C., Bostanci, B., Yol, S., & Akoglu, M. (2003). Distribution of hydatid cysts into the liver with reference to cystobiliary communications and cavity-related complications. *The American journal of surgery*, 185(2), 175-179.
- Nacef, K., Chaouch, M. A., Ben Khalifa, M., Chaouch, A., Ghannouchi, M., Maatouk, M., & Boudokhane, M. (2017). Liver hydatid cyst complicated by biliary and colonic fistula diagnosed after intra-operative cholangiography. *Surgical Infections Case Reports*, 2(1), 92-94.
- Atli, M., Kama, N. A., Yuksek, Y. N., Doganay, M., Gozalan, U., Kologlu, M., & Daglar, G. (2001). Intrabiliary rupture of a hepatic hydatid cyst: associated clinical factors and proper management. *Archives of Surgery*, 136(11), 1249-1255.
- Gharbi, H. A., Hassine, W., Brauner, M. W., & Dupuch, K. (1981). Ultrasound examination of the hydatid liver. *Radiology*, 139(2), 459-463.
- Bismuth, H. (1982). Surgical anatomy and anatomical surgery of the liver. *World journal of surgery*, 6(1), 3-9.
- Chaouch, M. A., Dougaz, M. W., Khalfallah, M., Jerraya, H., Nouria, R., Bouasker, I., & Dziri, C. (2019). A case report of complicated appendicular hydatid cyst mimicking an appendiceal mucocele. *Clinical journal of gastroenterology*, 1-4.
- Pinto, P., Gaete, S., & Vega, P. (2019). Utility of ERCP in the Diagnosis and Management of Biliary Complications of Hepatic Hydatid Disease. In *Echinococcosis*. IntechOpen.
- El Malki, H. O., El Mejdoubi, Y., Souadka, A., Mohsine, R., Ifrine, L., Abouqal, R., & Belkouchi, A. (2010). Predictive model of biliocystic communication in liver hydatid cysts using classification and regression tree analysis. *BMC surgery*, 10(1), 16.
- Unalp, H. R., Baydar, B., Kamer, E., Yilmaz, Y., Issever, H.,

- & Tarcan, E. (2009). Asymptomatic occult cysto-biliary communication without bile into cavity of the liver hydatid cyst: a pitfall in conservative surgery. *International Journal of Surgery*, 7(4), 387-391.
14. Reddy, A. D., & Thota, A. (2018). Cysto-biliary communication (CBC) in hepatic hydatidosis: predictors, management and outcome. *International Surgery Journal*, 6(1), 61-65.
 15. i Gavara, C. G., López-Andújar, R., Ibáñez, T. B., Ángel, J. M. R., Herraiz, Á. M., Castellanos, F. O., ... & Rodríguez, F. S. J. (2015). Review of the treatment of liver hydatid cysts. *World Journal of Gastroenterology: WJG*, 21(1), 124.
 16. Sáez-Royuela, F., Yuguero, L., López-Morante, A., Pérez-Álvarez, J. C., Martín-Lorente, J. L., & Ojeda, C. (1999). Acute pancreatitis caused by hydatid membranes in the biliary tract: treatment with endoscopic sphincterotomy. *Gastrointestinal endoscopy*, 49(6), 793-796.
 17. Kattan, Y. B. (1975). Intrabiliary rupture of hydatid cyst of the liver. *British Journal of Surgery*, 62(11), 885-890.
 18. Becker, K., Frieling, T., Saleh, A., & Häussinger, D. (1997). Resolution of hydatid liver cyst by spontaneous rupture into the biliary tract. *Journal of hepatology*, 26(6), 1408-1412.
 19. Kornaros SE, Aboul-Nour TA. Frank intrabiliary rupture of hydatid hepatic cyst: diagnosis and treatment. *J Am Coll Surg*. 1996 Nov;183(5):466-70.
 20. Ulualp, K. M., Aydemir, I., Senturk, H., Eyuboğlu, E., Cebeci, H., Unal, G., & Unal, H. (1995). Management of intrabiliary rupture of hydatid cyst of the liver. *World journal of surgery*, 19(5), 720-724.
 21. Akkapulu, N., Aytac, H. O., Arer, I. M., Kus, M., & Yabanoglu, H. (2018). Incidence and risk factors of biliary fistulation from a hepatic hydatid cyst in clinically asymptomatic patients. *Tropical doctor*, 48(1), 20-24.
 22. Delso, J. G., Larramona, S. F., Olmo, J. F., & Amezcaga, R. U. (2019). Acute cholangitis secondary to hydatid membranes in the biliary tract. *Gastrointestinal endoscopy*, 89(1), 199-200.
 23. Valle-Sanz Y del, Lorente-Ramos RM. Sonographic and computed tomographic demonstration of hydatid cysts communicating with the biliary tree. *Journal of Clinical Ultrasound*. 2004;32(3):144-148.
 24. Chaouch, M. A., Dougaz, M. W., Cherni, S., & Nouira, R. (2019). Daughter cyst sign in liver hydatid cyst. *Journal of Parasitic Diseases*, 1-2.
 25. Prousalidis, J., Kosmidis, C., Kapoutzis, K., Fachantidis, E., Harlaftis, N., & Aletras, H. (2009). Intrabiliary rupture of hydatid cysts of the liver. *The American Journal of Surgery*, 197(2), 193-198.
 26. Al-Bahrani, A. Z., Al-Maiyah, M., Ammori, B. J., & Al-Bahrani, Z. R. (2007). Factors predictive of frank intrabiliary rupture in patients with hepatic hydatid cysts. *Hepato-gastroenterology*, 54(73), 214-217.
 27. Atahan, K., Küpeli, H., Deniz, M., Gür, S., Çökmez, A., & Tarcan, E. (2011). Can occult cystobiliary fistulas in hepatic hydatid disease be predicted before surgery?. *International journal of medical sciences*, 8(4), 315.
 28. Marti-Bonmati, L., & Serrano, F. M. (1990). Complications of hepatic hydatid cysts: ultrasound, computed tomography, and magnetic resonance diagnosis. *Gastrointestinal radiology*, 15(1), 119-125.
 29. Laghi, A., Teggi, A., Pavone, P., Franchi, C., De Rosa, F., & Passariello, R. (1998). Intrabiliary rupture of hepatic hydatid cysts: diagnosis by use of magnetic resonance cholangiography. *Clinical infectious diseases*, 1465-1467.
 30. Jerraya, H., Khalfallah, M., Osman, S. B., Nouira, R., & Dziri, C. (2015). Predictive factors of recurrence after surgical treatment for liver hydatid cyst. *Surgical endoscopy*, 29(1), 86-93.
 31. Dziri, C., Dougaz, W., Samaali, I., Khalfallah, M., Jerraya, M., Mzabi, R., ... & Fingerhut, A. (2019). Radical surgery decreases overall morbidity and recurrence compared with conservative surgery for liver cystic echinococcosis: systematic review with meta-analysis. *Annals of Laparoscopic and Endoscopic Surgery*, 4.
 32. Yorganci, K., & Sayek, I. (2002). Surgical treatment of hydatid cysts of the liver in the era of percutaneous treatment. *The American journal of surgery*, 184(1), 63-69.
 33. El Malki, H. O., Amahzoune, M., Benkhraba, K., El Kaoui, H., Elmejdoubi, Y., Mohsine, R., ... & Belkouchi, A. (2006). Le traitement conservateur du kyste hydatique de la rate. *Médecine du Maghreb*, 139, 33-38.