

Dear Author,

Here are the final proofs of your article. Please check the proofs carefully.

Please note that at this stage you should only be checking for errors introduced during the production process. Please pay particular attention to the following when checking the proof:

- Author names. Check that each author name is spelled correctly, and that names appear in the correct order of first name followed by family name. This will ensure that the names will be indexed correctly (for example if the author's name is 'Patel, J.', she will be cited as 'Jane Patel').
- Affiliations. Check that all authors are cited with the correct affiliations, that the author who will receive correspondence has been identified with an asterisk (*), and that all equal contributors have been identified with a well sign (#).
- Ensure that the main text is complete.
- Check that figures, tables and their legends are included and in the correct order.
- Look to see that queries that were raised during copy-editing or typesetting have been resolved.
- Confirm that all web links are correct and working.
- Ensure that special characters and equations are displaying correctly.
- Check that additional or supplementary files can be opened and are correct.

Changes in scientific content cannot be made at this stage unless the request has already been approved. This includes changes to title or authorship, new results, or corrected values.

How to return your corrections

Returning your corrections via email:

- Annotate the proof PDF with your corrections.
- Remember to include the journal title, manuscript number, and your name when sending your response via email.

After you have submitted your corrections, you will receive email notification from our production team that your article has been published in the final version. All changes at this stage are final. We will not be able to make any further changes after publication.

Kind regards,

ANT PUBLISHING
CORPORATION

Iatrogenic Pneumothorax During Parathyroid Gland Biopsy: A Case Report

İsmail Ertuğrul GEDİK^{a*}

^aErzurum Regional Education and Research Hospital Thoracic Surgery Department.

Abstract

An important subgroup of traumatic pneumothoraces, iatrogenic pneumothorax may occur during a variety of invasive procedures, including surgeries. In this report, we present a case of iatrogenic pneumothorax that occurred during parathyroid gland biopsy. A 54-year-old male patient arrived at our clinic complaining of acute onset right-sided chest pain and dyspnea that occurred during parathyroid gland biopsy. The patient's physical examination revealed diminished respiratory sounds in the right hemithorax. Pneumothorax in the right hemithorax. Chest tube thoracostomy was immediately performed through the right fifth intercostal space. While air drainage ceased on the second post-procedure day, auscultation revealed diminished respiratory sounds in the right apical zone on the fourth post-procedure day. Chest x-ray was performed on the same day, revealing lung expansion defect. The chest tube was clamped and a chest x-ray was repeated two hours later, which showed no significant difference. The chest tube was removed. Control physical examination and chest x-ray did not reveal any significant abnormalities and the patient was discharged. It should always be kept in mind that perithoracic and cervical invasive procedures may cause iatrogenic pneumothorax.

Keywords: Pneumothorax; Thoracostomy; Biopsy; Fine-Needle; Iatrogenic Disease

INTRODUCTION

Pneumothorax is the pathological accumulation of air in the pleural cavity. Pneumothoraces can be spontaneous or traumatic. Iatrogenic pneumothorax (IPx) is an important subgroup of traumatic pneumothoraces. IPx may occur during many invasive procedures, including surgeries^[1]. Herein, we present a case of IPx resulting from parathyroid gland biopsy.

CASE REPORT

A 54-year-old male patient was consulted to our clinic with complaints of acute onset right-sided chest pain and dyspnea that occurred during parathyroid gland biopsy performed by the endocrinology clinic. The patient's physical examination findings were as follows:

blood pressure of 130/88 mm Hg, heart rate of 96/min, and respiratory rate of 26/min. Lung auscultation revealed diminished respiratory sounds in the right hemithorax. Posterior-anterior (PA) chest x-ray revealed a pneumothorax in the right hemithorax (Figure 1). Chest tube thoracostomy using a 28 French (Fr) drain was performed immediately through the intersection of the right fifth intercostal space and mid-axillary line. Air drainage stopped on the second post-procedure day, yet auscultation revealed diminished respiratory sounds in the right apical zone on the fourth post-procedure day. PA chest x-ray was performed on the same day, revealing lung expansion defect (Figure 2). The chest tube was clamped and PA chest x-ray was repeated 2 hours later, showing no significant difference. The chest tube was removed. Control physical examination and PA chest x-ray did not reveal any significant abnormalities. The patient was discharged and invited for a follow-up outpatient clinic examination.

DISCUSSION

Anatomy of the apical part of the parietal pleura is important

*Corresponding author: İsmail Ertuğrul GEDİK
Mailing address: Erzurum Regional Education and Research Hospital Thoracic Surgery Department, 25000, Erzurum/TURKEY.
E-mail: ertugrulgedik@gmail.com
Received: 30 December 2019 Accepted: 25 February 2020

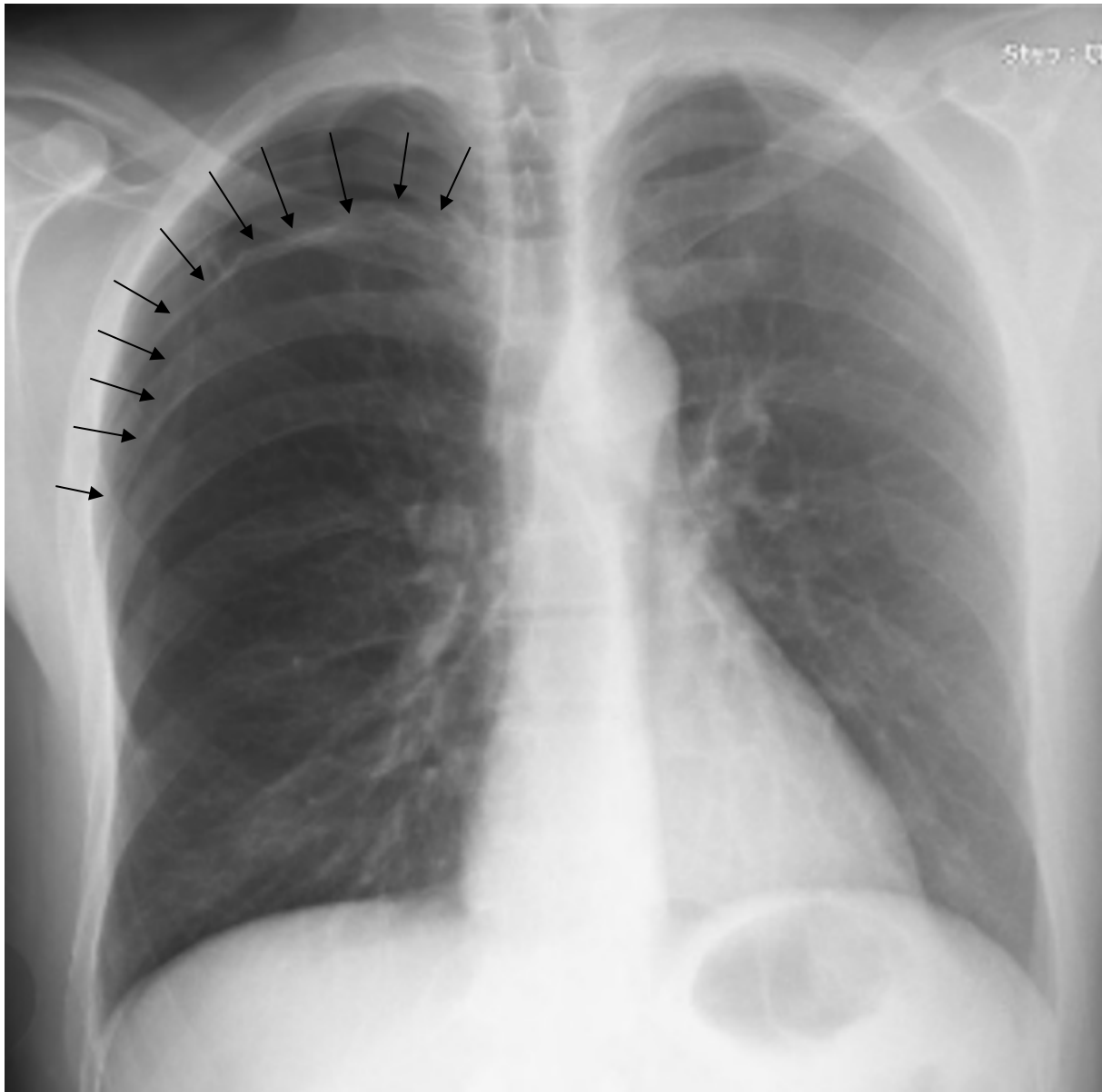


Figure 1. Right-sided pneumothorax on PA chest x-ray.

in understanding the etiopathophysiology of IPx. The upper part of the pleura and pulmonary apex occupy the thoracic inlet on both sides. Between the pleura and neck of the first rib are the superior intercostal artery, as well as the sympathetic trunk and ventral ramus of the first thoracic nerve. The internal thoracic artery enters the thorax between the first costal cartilage and pleura [1].

The most common cause of IPx is subclavian catheter insertion. Transthoracic/transbronchial fine needle biopsy and positive pressure mechanical ventilation are also among the top etiological procedures for IPx [2]. Additionally, IPx has been reported to occur during axillary lymph node biopsy, hypoglossal nerve stimulation, and acupuncture [3-5]. No case report of IPx occurrence during parathyroid gland biopsy

was found.

IPx incidence is reported to be 1.36%, increasing with the number of invasive interventions [6].

The pathophysiology of IPx is similar to non-iatrogenic traumatic pneumothoraces. In IPx, the visceral pleura is usually damaged, possibly leading to life-threatening tension pneumothorax. Thus, symptoms and signs include decreased or absent breath sounds on the affected side, pleuritic pain and dyspnea, tachypnea, and tachycardia. If tension pneumothorax is present, hypotension, bradycardia, and cardiopulmonary arrest may occur [7].

The diagnosis of IPx is also similar to non-iatrogenic types. In conjunction with physical examination findings, radiological methods such as PA chest x-ray, thoracic computerized

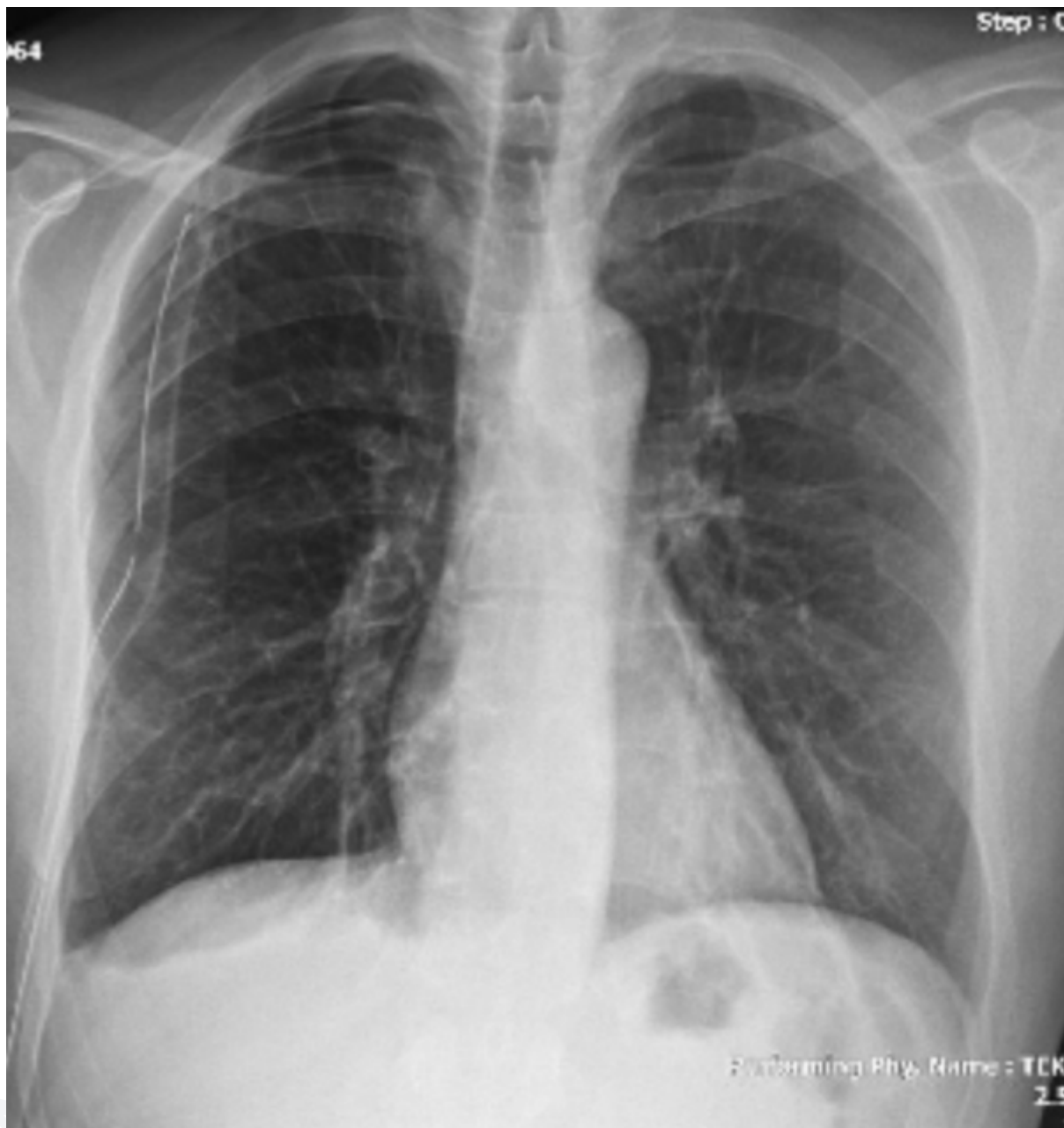

Figure 2. Right lung expansion defect seen on PA chest x-ray at fourth post-procedure day.

tomography, and thoracic ultrasonography may help the physician in diagnosing IPx [7].

There are several methods to calculate the amount of pneumothorax using radiological findings. We use Light index in our clinic for this calculation. In the Light index, the pneumothorax size is a function of the average diameter at the midpoint of the cranial half of the hemithorax (y) and the average diameter at the midpoint of the cranial half of the lung (x). Thus, the Light index is calculated as $\text{Light \%} = 100 - 100 \times (x/y)^3$ [8].

Treatment of IPx is similar to any other type of pneumothorax

and is dependent on severity. Simple observation with oxygen insufflation can be curative in cases of mild pneumothoraces (<20% of the volume of the involved hemithorax) as long as the patient is stable. Fine needle aspiration can also be considered as a treatment. Chest tube thoracostomy is the treatment of choice in large volume pneumothoraces and unstable cases [7]. In conclusion, it should always be kept in mind that perithoracic invasive procedures may cause IPx. If IPx is suspected, thoracic surgery clinics should be consulted immediately, thereby preventing potential morbidity and mortality attributable to pneumothorax.

DECLARATIONS

Authors' contributions

Made substantial contributions to conception and design of the study and performed data analysis and interpretation. Performed data acquisition, as well as provided administrative, technical, and material support: Gedik İ E.

Availability of Data and Materials

Not applicable.

Financial support and sponsorship

None.

Conflicts of interest

All authors declared that there are no conflicts of interest.

Ethical approval and consent to participate

Not applicable.

Consent for publication

Not applicable.

REFERENCES

1. Ojeda, J. R., & Hipskind, J. E. (2018). Pneumothorax, Iatrogenic.
2. Stefani, A., Ruggiero, C., Aramini, B., & Scamporlino, A. (2018). An unusual drain in the pleural cavity: iatrogenic pneumothorax due to pulmonary misplacement of a nasogastric tube. *Intensive care medicine*, 44(12), 2290-2291.
3. Arteaga, A. A., Pitts, K. D., & Lewis, A. F. (2018). Iatrogenic pneumothorax during hypoglossal nerve stimulator implantation. *American journal of otolaryngology*, 39(5), 636-638.
4. Tagami, R., Moriya, T., Kinoshita, K., & Tanjoh, K. (2013). Bilateral tension pneumothorax related to acupuncture. *Acupuncture in Medicine*, 31(2), 242-244.
5. Celik, B., Sahin, E., Nadir, A., & Kaptanoglu, M. (2009). Iatrogenic pneumothorax: etiology, incidence and risk factors. *The Thoracic and cardiovascular surgeon*, 57(05), 286-290.
6. Loisel, A., Parish, J. M., Wilkens, J. A., & Jaroszewski, D. E. (2013). Managing iatrogenic pneumothorax and chest tubes. *Journal of hospital medicine*, 8(7), 402-408.

7. Loisel A, Parish JM, Wilkens JA, Jaroszewski DE. Managing iatrogenic pneumothorax and chest tubes. *J Hosp Med*. 2013;8:402-8.
8. Salazar AJ, Aguirre DA, Ocampo J, Camacho JC, Díaz XA. Evaluation of three pneumothorax size quantification methods on digitized chest X-ray films using medical-grade grayscale and consumer-grade color displays. *J Digit Imaging*. 2014;27:280-6.

Author Query Form

Dear Author,

During the copy-editing of your paper, the following queries arose.

Please refer to the query reference call out numbers in the page proofs and respond to each by marking the necessary comments using the PDF annotation tools.

Please remember illegible or unclear comments and corrections may delay publication.

Many thanks for your assistance.

Query Reference	Query	Remark
Q1	Author: Please confirm that given names and surnames/ family names have been identified correctly.	✓
Q2	Affiliations: Please check if the affiliations are presented correctly.	✓
Q3	Corresponding author: Please check if the information are presented correctly.	✓
Q4	Please check if the reference is correct? You did not provide the 7th and 8th references.	✓
Q5	Please check if the chart annotation is correct?	✓