

# Delayed Presentation of Sciatic Nerve Injury after Total Hip Arthroplasty: Neurosurgical Considerations, Diagnosis, and Management

Linda W. Xu<sup>1</sup> Anand Veeravagu<sup>1</sup> Tej D. Azad<sup>1</sup> Ciara Harraher<sup>1</sup> John K. Ratliff<sup>1</sup>

<sup>1</sup>Department of Neurosurgery, Stanford University School of Medicine, Stanford, California, United States

J Neurol Surg Rep 2016;77:e134–e138.

Address for correspondence Anand Veeravagu, MD, Department of Neurosurgery, Stanford University School of Medicine, 300 Pasteur Drive, Stanford, CA 94305, United States (e-mail: anand.veeravagu@stanford.edu).

## Abstract

**Background** Total hip arthroplasty (THA) is an established treatment for end-stage arthritis, congenital deformity, and trauma with good long-term clinical and functional outcomes. Delayed sciatic nerve injury is a rare complication after THA that requires prompt diagnosis and management.

**Methods** We present a case of sciatic nerve motor and sensory deficit in a 52-year-old patient 2 years after index left THA. Electromyography (EMG) results and imaging with radiographs and CT of the affected hip demonstrated an aberrant acetabular cup screw in the posterior-inferior quadrant adjacent to the sciatic nerve.

**Case Description** The patient underwent surgical exploration that revealed injury to the peroneal division of the sciatic nerve due to direct injury from screw impingement. A literature review identified 11 patients with late-onset neuropathy after THA. Ten patients underwent surgical exploration and pain often resolved after surgery with 56% of patients recovering sensory function and 25% experiencing full recovery of motor function.

**Conclusions** Delayed neuropathy of the sciatic nerve is a rare complication after THA that is most often due to hardware irritation, component failure, or wear-related pseudotumor formation. Operative intervention is often pursued to explore and directly visualize the nerve with limited results in the literature showing modest relief of pain and sensory symptoms and poor restoration of motor function.

## Keywords

- ▶ total hip arthroplasty
- ▶ delayed neuropathy
- ▶ sciatic nerve
- ▶ operative outcome

## Introduction

Approximately 225,000 primary total hip arthroplasties (THAs) are performed in the United States per year, and projections indicate that more than 4 million THAs will be performed annually by 2030.<sup>1</sup> Neurologic injury after THA is reported to occur in 0.09 to 3.7% of primary THAs and 0 to 7.4% of revision THAs.<sup>2</sup> Noted causes of neurologic injury include direct intraoperative nerve injury, leg lengthening, excess retraction, cement extravasation, cement-related thermal damage, patient positioning, and postoperative hematoma.<sup>2</sup> The majority of these injuries are symptomatic

within the early postoperative period and can be managed conservatively with close follow-up. Delayed onset of neurologic injury is a rare complication with a unique differential diagnosis requiring appropriate management.

We report a case of neuropathy caused by malposition of an acetabular cup screw causing direct injury to the sciatic nerve. The patient developed progressively worsening loss of ankle dorsiflexion, resulting in complete footdrop 2 years after initial THA. The presentation, intervention, and outcome of other cases of delayed neuropathy are reviewed in the present report. Delayed neuropathies are most often caused by irritation from hardware, component failure, or wear-related pseudotumors.

received  
December 23, 2015  
accepted after revision  
October 11, 2015

DOI <http://dx.doi.org/10.1055/s-0035-1568134>.  
ISSN 2193-6358.

© 2016 Georg Thieme Verlag KG  
Stuttgart · New York

License terms



## Case Report

### Initial Operative Intervention

The patient was a 52-year-old woman with end-stage arthritis of her bilateral hips with previous uncomplicated right THA that underwent an elective left THA. No intraoperative complications, abnormal anatomic landmarks, or events were noted at the time of surgery. Fluoroscopy confirmed equal limb lengths and appropriate hardware placement.

### Re-presentation and Examination

The patient's initial orthopedic postoperative course was complicated by paresthesias of the right lower extremity, severe hypesthetic pain primarily in the lateral and anterior aspect of the right calf, and severe sciatica. During her hospital stay, the patient's sensation and pain improved; however, less than 1 year after her THA she noted gradual onset of weakness in her right lower extremity.

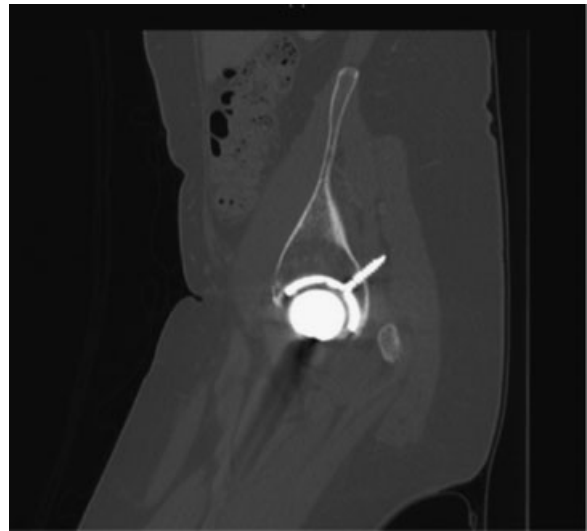
Two years after THA she presented to our neurosurgical clinic. At that time, she had developed a complete footdrop with loss of ankle dorsiflexion and required the use of an ankle-foot orthosis (AFO) to ambulate. She underwent an EMG at an outside facility, had a neurologic evaluation, and was undergoing physical therapy. Her only significant medical history was hypertension.

On physical examination, the patient had 0/5 dorsiflexion strength with 3/5 eversion and 5/5 inversion and plantar-flexion strength. She had no Tinel sign over the fibular head. Decreased sensation was noted in the lateral aspect of the leg and the dorsum of the foot. She had no gross deformity of the lower extremity and had normal quadriceps and hamstring strength at the knee and the hip.

EMG showed severely reduced amplitude of the peroneal compound muscle action potentials and unrecordable superficial peroneal sensory response. There was also mild prolongation of bilateral tibial F-wave latency. Fibrillation potentials were seen in the peroneal division of the sciatic nerve with minimal evidence of reinnervation changes to the muscle units. This was indicative of sciatic neuropathy exclusively involving the peroneal division. This localized the lesion to proximal to the short head of the bicep femoris muscle. This led to obtaining advanced imaging consisting of a computed tomography (CT) of the pelvis, which demonstrated a malpositioned acetabular cup screw within the soft tissues adjacent to the sciatic nerve (► Fig. 1).

### Operation

The patient underwent a buttock-level exploration of the sciatic nerve complex. The sciatic nerve was dissected via internal neurolysis into peroneal and tibial divisions at the level of the buttock. The division of the sciatic complex was dissected proximally to the exit of the sciatic from the pelvis. The peroneal portion of the nerve was found to be compromised by the malpositioned screw. There was no neuroma identified at the site of nerve compression, although there was evidence of nerve displacement by the protruding screw. The nerve was stimulated locally and nerve action potentials were recorded proximal and distal to the site of injury. Both



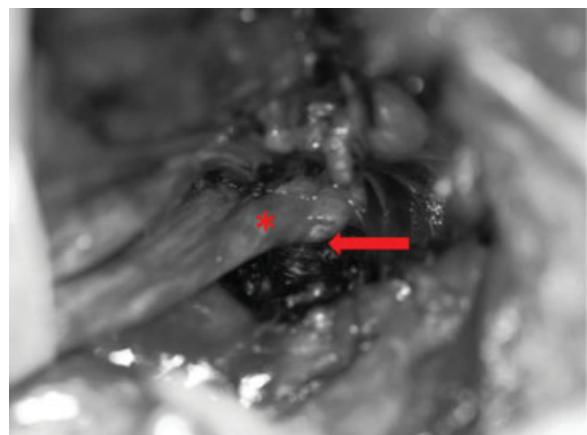
**Fig. 1** CT scan of hip showing malpositioned and long acetabular cup screw.

peroneal and tibial portions of the nerve were tested separately to avoid false-positive conduction from the tibial division. The intraoperative recordings showed preservation of conduction across the site of nerve impingement (► Fig. 2).

The nerve was reflected off the head of the screw and gently moved proximally toward the sciatic notch. An external neurolysis of the peroneal division was performed. When the nerve was free of the screw and protected, a titanium cutting drill bit was used to shorten the screw so that it was flush with the bony interface. Repeated stimulation of the nerve confirmed that action potentials were still able to propagate past the site of injury.

### Postoperative Course

The patient is now 2 years out of surgery and has demonstrated some recovery of peroneal nerve function, supporting the decision to pursue external neurolysis. The patient's improvement has not been complete and the patient requires an external orthosis.



**Fig. 2** Intraoperative photo showing acetabular screw impinging on the peroneal division of the sciatic nerve. Arrow, THA screw; Asterisk, peroneal division.

## Discussion

THA is a widely used procedure for the treatment of end-stage hip arthritis that is able to restore functional ability to hundreds of thousands of patients a year in the United States. Postoperative neurologic injury is a devastating complication with significant morbidity and functional limitations. There is a known risk of immediate neuropathy from mechanisms such as intraoperative compression from retractors, hematoma, limb lengthening, and inappropriate patient positioning. However, there is also a rarer risk of delayed neuropathy after THA that has different causative pathologies. Our findings from the literature suggest that late complications from THA may be more likely due to migration of hardware over time with subsequent nerve compression or reactive mass or fluid collection. In our case, a long, malpositioned screw was found in the soft tissue compressing the peroneal branch of the sciatic nerve.

## Literature Review

A search of the PubMed database was conducted using the search term “delayed neuropathy after total hip arthroplasty” covering the years 1950 through 2015. Fifteen case reports on 16 patients were selected based on involvement of a neuropathy that appeared after THA.<sup>3–12</sup>

Patients presenting prior to 1 month included those that developed postoperative hematomas, had poor patient positioning, had previously undiagnosed hereditary neuropathy with liability to pressure palsies (HNPPs), or had anesthetic-induced inflammatory neuropathy and were felt to qualify as early postoperative complications. Delayed onset was defined as those with neuropathies developing over 1 month from surgery. The initial presentations, interventions, and outcomes are outlined in ►Table 1.

**Table 1** Summary of literature review of cases of delayed neuropathy after total hip arthroplasty

Case report	Time of presentation	Clinical presentation	Workup	Intervention	Identified injury	Outcome
Fokter et al <sup>8</sup>	9 y	P: Left groin and thigh pain radiation to the knee S: Hypoesthesia in anteromedial thigh M: Quadriceps weakness R: Loss of patellar reflex	X-ray: Eccentric location of femoral head in shell showing liner wear MRI spine: Normal EMG: Lesion localized to left lumbosacral plexus with denervation in femoral distribution CT: 13-cm intrapelvic cyst	Lower middle laparotomy and removal of pelvic cyst Revision hip arthroplasty with allograft used to repair defect	Wear debris mass	Full recovery of function
May et al	4 mo	S: Mild numbness in foot	None	None	Limb lengthening	Full recovery of function
May et al	5 mo	P: Pain in foot S: Sensory deficit in big toe	EMG	Interpositioning of fat pad between sciatic nerve and acetabular ring	Reinforcement ring implantation and scar tissue	Resolution of pain Developed foot drop 6 mo after reoperation
Bader et al <sup>4</sup>		S: Numbness in anterior and medial aspect of thigh M: Weak knee extension	EMG: 60% loss of motor conduction in femoral nerve	Nerve separation from scar tissue, removal of granuloma and acetabular ring	Loosening of acetabula implant and migration, fracture of supplemental screw, granuloma formation	Full recovery of sensory function Motor improved to 20% of function
Katsimihahas et al <sup>9</sup>	5 mo	S: Lateral calf, foot, posterior leg R: absent ankle jerk M: Weakness in ankle dorsiflexors, evertors, and invertors	EMG: Sciatic nerve deficit at level of the hip or proximal thigh in tibialis anterior, peroneus longus, and gastrocnemius MRI: Spine, gluteus, and pelvis unrevealing	AFO		Improvement in muscle strength and sensation, not back to baseline

**Table 1** (Continued)

Case report	Time of presentation	Clinical presentation	Workup	Intervention	Identified injury	Outcome
Fischer et al <sup>7</sup>	7 y	P: Lower buttock, difficulty with ambulation	EMG: Normal CT: Large fluid collection deep to abductor extending through greater sciatic notch Arthrogram: Fistula between joint and pelvic fluid collection	L4–5 foraminotomy IR drainage of fluid collection Removal of fractured polyethylene liner and use of bone allograft, cyst resection, replacement of hardware	Cyst formation from THA wear debris	Resolution of pain Able to ambulate unassisted
Stiehl and Stewart <sup>12</sup>	6 mo	P: Left foot S: Left foot	Bone scan: No increased uptake EMG: Deficit in gluteus medius, tibialis anterior, flexor digitorum longus, biceps femoris, gastrocnemius	Screw removal, dissection of nerve away from injury site	Pelvic screw migration compressing sciatic nerve	Resolution of pain Numbness persistent Motor function improved to 60%
Asnis et al <sup>3</sup>	5 y	P: Buttock and thigh S: Posterior thigh M: Hamstring weakness R: Decreased ankle jerk	X-ray: Normal lumbosacral region; pelvis showing wire migration	Lidocaine injection Sciatic exploration showing 2 cm wire within sciatic nerve, epineurium incised and wire removed	Migration of trochanteric wire	Full recovery of function
Edwards et al <sup>6</sup>	3 y	P: Buttock, posterior thigh to toe S: Dorsum of foot and lateral calf M: Tibialis anterior, extensor digitorum longus, extensor hallucis longus R: Absent ankle jerk	X-ray: Normal EMG: Deficit in tibialis anterior, extensor hallucis longus, short head of biceps femoris Myelogram: Normal	Sciatic nerve exploration; spur of methyl methacrylate found eroding through lateral side of sciatic, neurolysis and shaving down spur	Methyl methacrylate spur	Immediate pain relief Decrease in area of sensory loss No motor recover
Casagrande and Danahy <sup>5</sup>	7 mo	P: Foot pain M: Peroneal weakness	EMG: Deficit in peroneal and tibial distribution	Sciatic nerve block and lumbar sympathetic block Sciatic exploration showing dense scar tissue, sciatic neurolysis and acrylic mass excision, osteotomy of ischial tuberosity	Acrylic mass, scar tissue	Pain resolved No motor recovery
Leinung et al <sup>10</sup>	10 y	P: Thigh pain M: Weakness in femoral distribution	CT: Large pelvic mass	Wide excision of tumor	Inflammatory pseudotumor of iliopsoas	

(Continued)

**Table 1** (Continued)

Case report	Time of presentation	Clinical presentation	Workup	Intervention	Identified injury	Outcome
Xu et al	2 y	S: Lateral leg and dorsum of foot M: Absence of dorsiflexion, weakness in ankle eversion	MRI: Atrophy of extensor muscles EMG: Deficits in peroneal distribution of sciatic nerve CT: Displacement of screw	Sciatic exploration with dissection of nerve off of screw; shaving down screw	Screw displacement and compression of sciatic nerve	Persistent motor and sensory loss

Abbreviations: AFO, ankle-foot orthosis; CT, computed tomography; EMG, electromyography; IR, interventional radiology; MRI, magnetic resonance imaging; THA, total hip arthroplasty.

Eleven patients were defined as having late-onset neuropathies. Date of presentation ranged from 4 months to 9 years postoperatively. Presenting symptoms included eight patients with pain, nine with sensory deficits, eight with motor deficits, and four with loss of reflexes. Regarding patient workup, three received hip radiographs, four had CTs, two had magnetic resonance imaging (MRIs), and nine underwent EMGs. Ten patients received operative intervention, whereas one was treated conservatively with a brace and one with no intervention. Mechanisms of injury include three patients with mass formation adjacent to the construct, one patient with limb-lengthening injury, and seven patients with hardware migration and compression. Of those with mass formation next to the construct, one was felt to be inflammatory pseudotumor whereas two were felt to be wear-related cysts caused by metal debris. After intervention, four patients made a full recovery of function, whereas six out of eight patients with preintervention motor deficits had persistent motor deficits and one without preintervention motor deficits developed a foot drop postoperatively. Out of the nine patients with sensory deficits, four had persistent sensory loss after intervention.

## Evaluation of Delayed Neuropathy

Patients with delayed neuropathy varied in presentation with pain, sensory, and motor symptoms. Most patients were evaluated with an EMG that can objectively quantify degree of motor compromise and aid in lesion localization.

As the causes of delayed nerve injury are largely local anatomical changes, CT and MRI can be helpful in identifying the cause of neuropathy. EMG localization of the level of deficit, combined with screw malposition, suggested that it was the cause of the patient's sensory and motor loss.

## Conclusion

Delayed neuropathy is a rare complication after primary THA that can be caused by hardware irritation as in the present case. Patients can present with pain, sensory loss, motor loss, and decreased reflexes that are best worked up with EMG to localize the area of neuropathy and imaging to identify the root source.

Results from the literature show that operative intervention is often pursued to explore and directly visualize the nerve with limited results in the literature showing modest relief of pain and sensory symptoms and poor restoration of motor function.

### Note

Linda W. Xu and Anand Veeravagu authors contributed equally to this manuscript.

## References

- Kurtz S, Ong K, Lau E, Mowat F, Halpern M. Projections of primary and revision hip and knee arthroplasty in the United States from 2005 to 2030. *J Bone Joint Surg Am* 2007;89(4):780–785
- Brown GD, Swanson EA, Nercessian OA. Neurologic injuries after total hip arthroplasty. *Am J Orthop* 2008;37(4):191–197
- Asnis SE, Hanley S, Shelton PD. Sciatic neuropathy secondary to migration of trochanteric wire following total hip arthroplasty. *Clin Orthop Relat Res* 1985;(196):226–228
- Bader R, Mittelmeier W, Zeiler G, Tokar I, Steinhäuser E, Schuh A. Pitfalls in the use of acetabular reinforcement rings in total hip revision. *Arch Orthop Trauma Surg* 2005;125(8):558–563
- Casagrande PA, Danahy PR. Delayed sciatic-nerve entrapment following the use of self-curing acrylic. A case report. *J Bone Joint Surg Am* 1971;53(1):167–169
- Edwards MS, Barbaro NM, Asher SW, Murray WR. Delayed sciatic palsy after total hip replacement: case report. *Neurosurgery* 1981; 9(1):61–63
- Fischer SR, Christ DJ, Roehr BA. Sciatic neuropathy secondary to total hip arthroplasty wear debris. *J Arthroplasty* 1999;14(6):771–774
- Fokter SK, Repse-Fokter A, Takac I. Case report: femoral neuropathy secondary to total hip arthroplasty wear debris. *Clin Orthop Relat Res* 2009;467(11):3032–3035
- Katsimihis M, Hutchinson J, Heath P, Smith E, Travlos J. Delayed transient sciatic nerve palsy after total hip arthroplasty. *J Arthroplasty* 2002;17(3):379–381
- Leinung S, Schönfelder M, Würfl P. [Inflammatory pseudotumor of the iliopectus muscle with femoral paralysis caused by massive metal abrasion of a hip endoprosthesis]. *Chirurg* 2002;73(7):725–728
- May O, Girard J, Hurtevent JF, Migaud H. Delayed, transient sciatic nerve palsy after primary cementless hip arthroplasty: a report of two cases. *J Bone Joint Surg Br* 2008;90(5):674–676
- Stiehl JB, Stewart WA. Late sciatic nerve entrapment following pelvic plate reconstruction in total hip arthroplasty. *J Arthroplasty* 1998;13(5):586–588