

Spontaneous fragmentation of a double J ureteral stent in a patient with a single anatomical kidney

Mayele Modeste^a, Nedjim Abdelkerim Saleh^{a,*}, Gallouo Messian^a, Hagguir Hissein^a, Abdi El Mostapha^a, Moataz Amine^a, Dakir Mohamed^a, Debbagh Adil^a, Aboutaieb Rachid^a

^a Department of Urology, Ibn Rochd University Hospital and Faculty of Medicine and Pharmacy, Casablanca, Morocco.

Abstract

Double J ureteral stents have become a fundamental practice in endo-urology. However, their use is not always without consequences. Fragmentation is a rare and dreaded complication, only a few sporadic cases have been reported in the literature. We are reporting a case of spontaneous fragmentation of double J ureteral stent in a 70-year-old patient who had undergone a simple right-side nephrectomy for the nonfunctioning kidney of lithiasis origin. Two years later, the patient consulted for severe left side loin pain, the biological and radiological based diagnosis was an obstructive renal failure on a single anatomical kidney, the condition was managed urgently by a double J ureteral stenting, and the patient was programmed for rigid ureteroscopy but he stayed out of sight for two years re-consulting after the emission of the distal end of his double J ureteral stent and calculus during urination. The radiographic assessment performed showed a double J ureteral stent fragmented into several pieces. Therapeutic management consisted of extraction of the fragments of the double J stent by ureteroscopy.

Keywords: Lithiasis, ureteral catheter JJ, complication, fragmentation, endourology

INTRODUCTION

Double J ureteral stents have become one of the most popular procedures in urology. There are different indications for their use. For some reason, they may be neglected for a long time despite their importance. A forgotten or neglected double J ureteral stent has its complications such as encrustation, immigration, urinary tract infection, and fragmentation^[1]. Fragmentation is rare and the most feared complication^[2]. We are reporting a case of two-year neglected double J ureteral stent fragmentation in a 70-year-old patient who had undergone a simple right-side nephrectomy

for the nonfunctioning kidney of lithiasis origin. Management was endoscopic, extraction of the double J fragments by ureteroscopy.

CASE REPORT

A 70 years old patient, with a low school education level, without any comorbidity, with a two-year history of a double J ureteral stent of 7 mm and 1200 Hounsfield for lithiasis of the left pelvic ureter and right nephrectomy of lithiasis origin. stayed out of sight after surgery, he presented following the release of stones and double J fragments (Figure 1). Clinically, the patient was conscious, hemodynamically stable. The temperature was 37.4 °C. Presence of a right lumpectomy scar (nephrectomy sequela) with left lumbar tenderness. Renal function was 23 mg/l with a clearance of 26.7. The radiological workup (unprepared urinary tree and euro scanner) revealed a double J ureteral catheter fractured into 3 fragments (Figure 2). Extraction of the fragments was done under ureteroscopy.

* Corresponding author: Nedjim Abdelkerim Saleh
Mailing address: Department of Urology, Ibn Rochd University Hospital and Faculty of Medicine and Pharmacy, Casablanca, Morocco.

E-mail: nedjimsaleh@gmail.com

Received: 26 February 2021 / Accepted: 13 June 2021

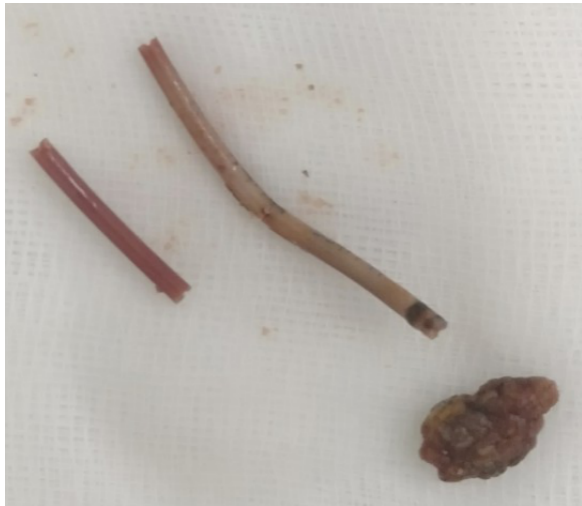

Figure 1. Fragments of double J ureteral catheter and calculus expelled during urination.

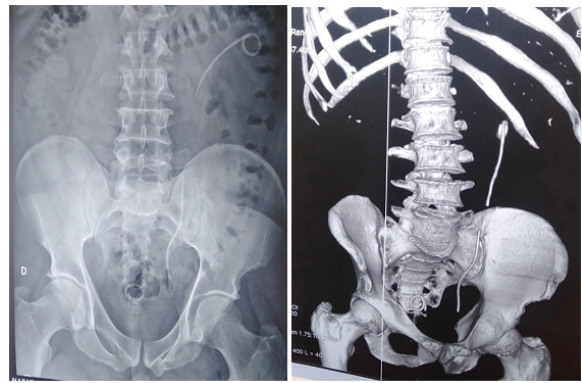


Figure 2. Unprepared urinary tree and uro-sanner showing a fragmented and biodegraded double J-stent.

DISCUSSION

Ureteral stents have been widely used for more than two decades with different indications. Due to the widespread use of ureteral stents, the number of complications has increased, including stent migration, encrustation, stone formation and fragmentation [3]. Of all complications, fragmentation of ureteral stents has been reported sporadically and is considered rare [4] and is the most feared complication of double J stent [2]. In a series of 290 patients, El-Faqih et al. reported that fragmentation was observed in 0.3% [5]. We report a case of two years of neglected double J ureteral stent fragmentation in a 70-year-old patient with a history of nephrectomy on a destroyed kidney of lithiasis origin.

The main risk factors for double J-stent complications are low education, stent duration, infections, chronic

kidney disease, lithiasis, congenital and metabolic abnormalities, and malignant ureteral obstruction due to hyperuricosuria chemotherapy [6]. A few factors were noted in our patient: low level of education, duration of catheterization, lithiasis.

Numerous mechanisms that can cause fragmentation of double J ureteral catheters were mentioned. The most common is infection. Depolymerization occurs on the material following infection. Another mechanism is the aging of the stent. A failure of the mechanism due to aging may develop and the stent may become brittle instead of flexible [7]. Ideal biomaterials include biological inertia, chemical stability in urine, resistance to infection and encrustation, long-term urine flow, stability, freedom from discomfort and affordability [8]. Low back pain, symptoms of bladder irritation and fever are signs of early complications associated with polyurethane ureteral stents. Late complications, such as encrustation, infection, and fragmentation, are more troublesome in terms of management [9]. Spontaneous fragmentation and excretion of fragments in the urine are extremely rare [10]. The main symptomatology prompting our patient to consult was Centuria. Low back pain was noted during the physical examination. Beyond the clinical presentation, and alteration of renal function may occur, as in our case.

Senol et al recommend the systematic performance of the CT scan in all patients with forgotten or neglected stents [11]. The CT scan was performed on our patient. The CT scan allows a better evaluation of the urinary system and allows the definition of an operative approach.

The management of neglected or forgotten double J stents can be long, difficult, complex, risky and costly [12]. Various combinations of endo-urological methods have been reported in the literature. However, there are no algorithmic approaches in urological guidelines for forgotten stents, which means that their treatment can be challenging for the urologist [11]. In our case, the therapeutic management was by endoscopic, ureteroscopic extraction of the fragments.

CONCLUSION

Complicated double J ureteral stents can pose a real challenge to the urologist. Their insertion should not be considered an innocuous procedure. Their indication must be well thought out. Patient education and a reminder system are important to avoid this type of complication which can cause morbidities and mortalities.

DECLARATIONS

Authors' contributions

All the authors contributed substantially to the design and production of this article.

Conflict of interest

All authors declared that there are no conflicts of interest.

REFERENCES

1. Al-Hajjaj, M., & Dababo, A. (2021). A missed fragmented double J ureteral stent for two years: Case report. *Urology Case Reports*, 34, 101505.
2. Chua, M. E., & Morales Jr, M. L. (2012). Spontaneous fracture of indwelling polyurethane ureteral stents: A case series and review of literature. *Canadian Urological Association Journal*, 6(5), 386.
3. Kilciler, M., Erdemir, F., Bedir, S., Coban, H., Erten, K., Guven, O., & Topac, H. (2006). Spontaneous ureteral stent fragmentation: a case report and review of the literature. *The Kaohsiung journal of medical sciences*, 22(7), 363-366.
4. Zisman, A., Siegel, Y. I., Siegmann, A., & Lindner, A. (1995). Spontaneous ureteral stent fragmentation. *The Journal of urology*, 153(3), 718-721.
5. El-Faqih, S. R., Shamsuddin, A. B., Chakrabarti, A., Atassi, R., Kardar, A. H., Osman, M. K., & Husain, I. (1991). Polyurethane internal ureteral stents in treatment of stone patients: morbidity related to indwelling times. *The Journal of urology*, 146(6), 1487-1491.
6. Singh, I., Gupta, N. P., Hemal, A. K., Aron, M., Seth, A., & Dogra, P. N. (2001). Severely encrusted polyurethane ureteral stents: management and analysis of potential risk factors. *Urology*, 58(4), 526-531.
7. Hikmet, T., Sercan, S., Ugur, O. H., Burhan, B., Harun, O., Muslim, B., ... & Hamit, E. (2015). A new method for fragmented ureteral stent extraction: flexible renoscopy. *Urology case reports*, 3(6), 190-192.
8. Beiko, D. T., Knudsen, B. E., Watterson, J. D., Cadieux, P. A., Reid, G., & Denstedt, J. D. (2004). Urinary tract biomaterials. *The Journal of urology*, 171(6), 2438-2444.
9. Kuyumcuoglu, U., Eryildirim, B., Tuncer, M., Faydaci, G., Tarhan, F., & Oztugul, A. (2012). Effectiveness of medical treatment in overcoming the ureteral double-J stent related symptoms. *Canadian Urological Association Journal*, 6(6), E234.
10. Singh, V., & Gupta, A. (2009). Stenturia: a rare complication of indwelling ureteral stent. *Urol J*, 6(3), 226-227.
11. Adanur, S., & Ozkaya, F. (2016). Challenges in treatment and diagnosis of forgotten/encrusted double-J ureteral stents: the largest single-center experience. *Renal failure*, 38(6), 920-926.
12. Sancaktutar, A. A., Soyulemez, H., Bozkurt, Y., Penbegül, N., & Atar, M. (2012). Treatment of forgotten ureteral stents: how much does it really cost? A cost-effectiveness study in 27 patients. *Urological research*, 40(4), 317-325.