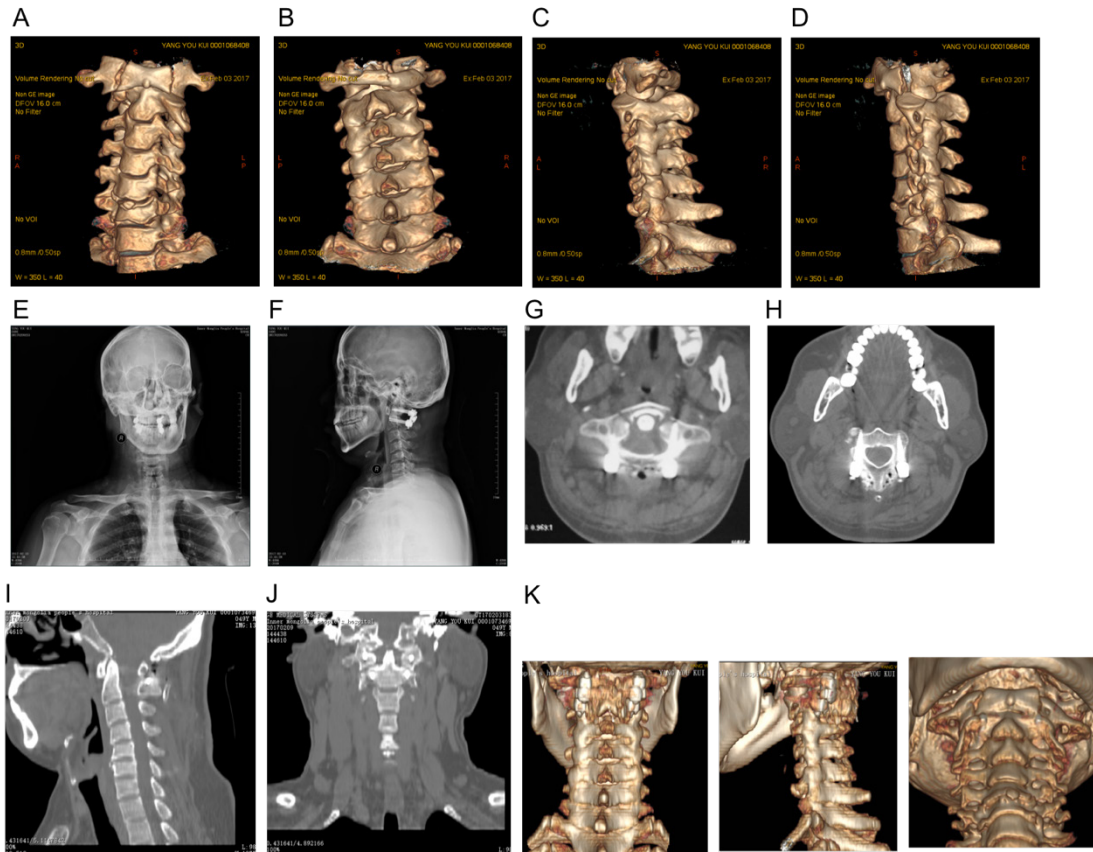
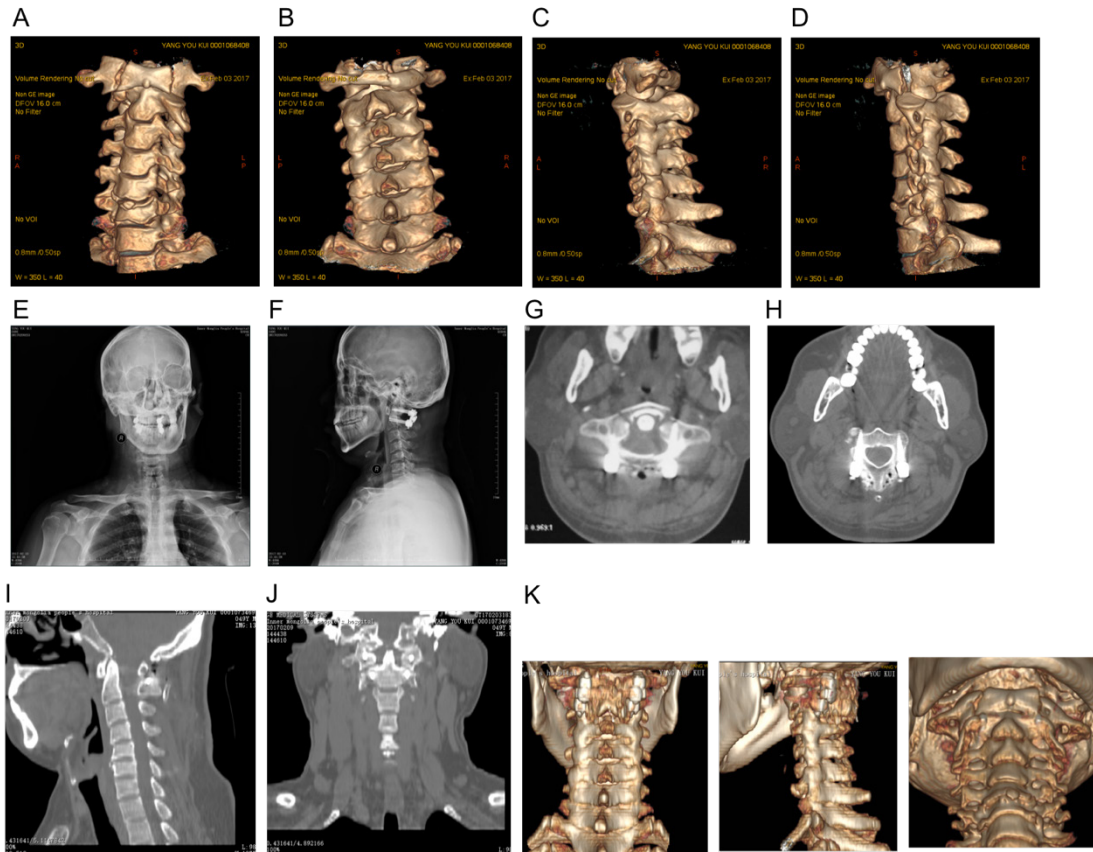


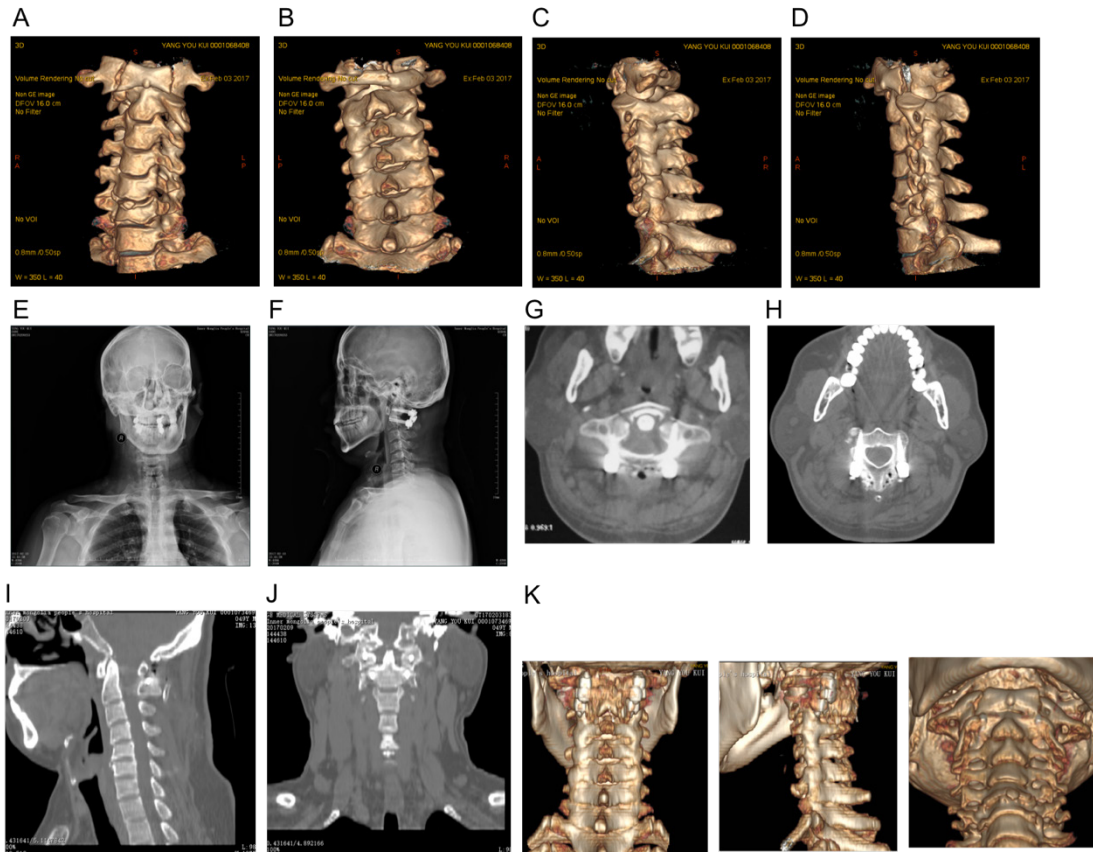
Supplementary Fig. 1. Typical case: a 39-year-old male with trauma caused by neck injury and limited activity. A. Anterior arch fracture of the atlas showed by CT. B. Posterior arch fracture of the atlas showed by CT. C. Anterior arch double fracture of the atlas showed by CT. D. Atlantoaxial dislocation showed by CT. E. Internal fixation in place showed by postoperative X-ray. F. Good reset of fracture dislocation. G. Accurate atlantoaxial fixation showed by postoperative CT plain scan. H. Reset of fracture dislocation showed by postoperative CT plain scan. I. Postoperative CT reconstruction of the sagittal site showed good reset of atlantoaxial dislocation. J. Postoperative CT reconstruction of the coronal site showed good reset of atlantoaxial dislocation. K. Postoperative CT 3D reconstruction showed reliable internal fixation and good reset of atlantoaxial fracture dislocation.



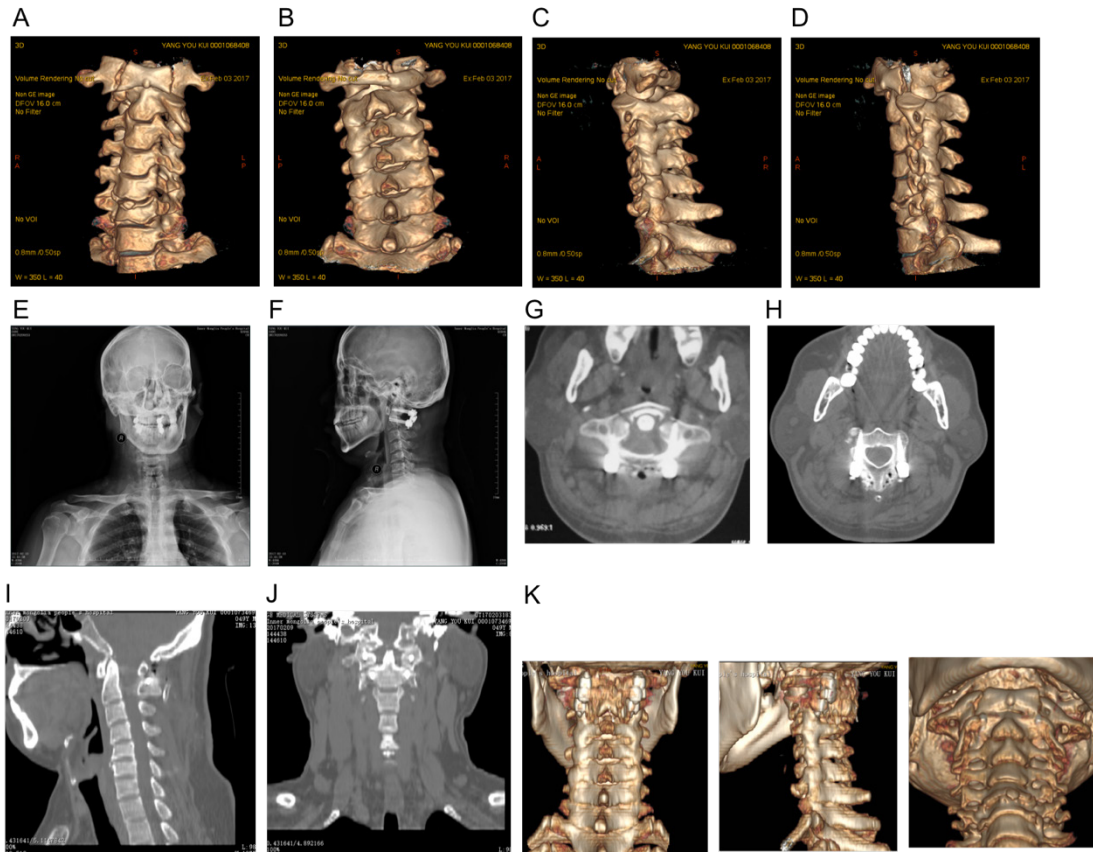
Supplementary Fig. 1. Typical case: a 39-year-old male with trauma caused by neck injury and limited activity. A. Anterior arch fracture of the atlas showed by CT. B. Posterior arch fracture of the atlas showed by CT. C. Anterior arch double fracture of the atlas showed by CT. D. Atlantoaxial dislocation showed by CT. E. Internal fixation in place showed by postoperative X-ray. F. Good reset of fracture dislocation. G. Accurate atlantoaxial fixation showed by postoperative CT plain scan. H. Reset of fracture dislocation showed by postoperative CT plain scan. I. Postoperative CT reconstruction of the sagittal site showed good reset of atlantoaxial dislocation. J. Postoperative CT reconstruction of the coronal site showed good reset of atlantoaxial dislocation. K. Postoperative CT 3D reconstruction showed reliable internal fixation and good reset of atlantoaxial fracture dislocation.



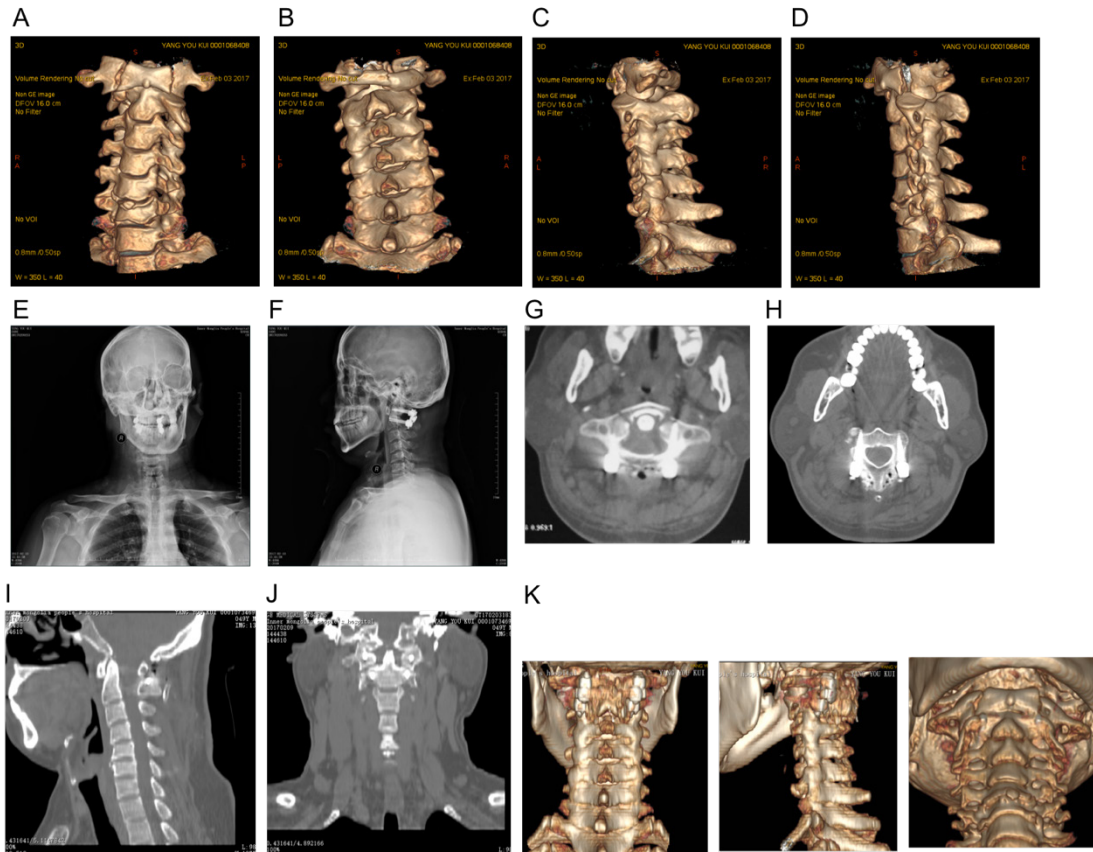
Supplementary Fig. 1. Typical case: a 39-year-old male with trauma caused by neck injury and limited activity. A. Anterior arch fracture of the atlas showed by CT. B. Posterior arch fracture of the atlas showed by CT. C. Anterior arch double fracture of the atlas showed by CT. D. Atlantoaxial dislocation showed by CT. E. Internal fixation in place showed by postoperative X-ray. F. Good reset of fracture dislocation. G. Accurate atlantoaxial fixation showed by postoperative CT plain scan. H. Reset of fracture dislocation showed by postoperative CT plain scan. I. Postoperative CT reconstruction of the sagittal site showed good reset of atlantoaxial dislocation. J. Postoperative CT reconstruction of the coronal site showed good reset of atlantoaxial dislocation. K. Postoperative CT 3D reconstruction showed reliable internal fixation and good reset of atlantoaxial fracture dislocation.



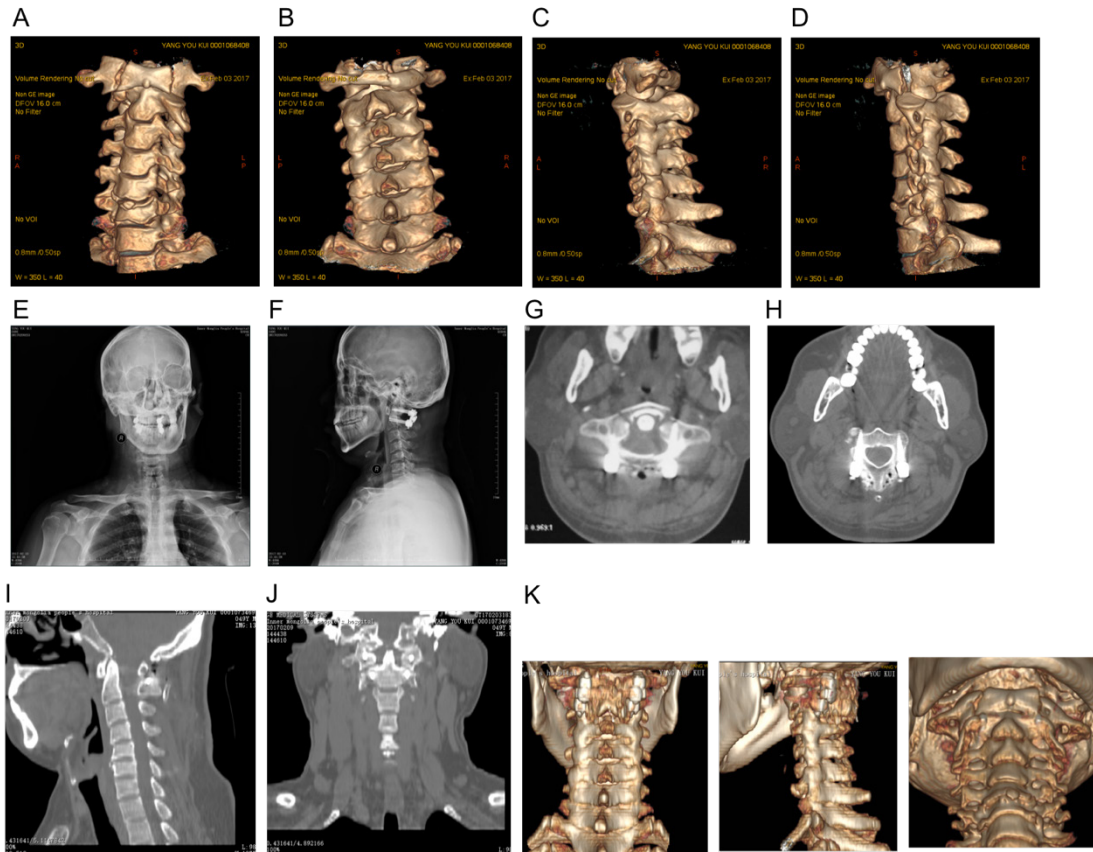
Supplementary Fig. 1. Typical case: a 39-year-old male with trauma caused by neck injury and limited activity. A. Anterior arch fracture of the atlas showed by CT. B. Posterior arch fracture of the atlas showed by CT. C. Anterior arch double fracture of the atlas showed by CT. D. Atlantoaxial dislocation showed by CT. E. Internal fixation in place showed by postoperative X-ray. F. Good reset of fracture dislocation. G. Accurate atlantoaxial fixation showed by postoperative CT plain scan. H. Reset of fracture dislocation showed by postoperative CT plain scan. I. Postoperative CT reconstruction of the sagittal site showed good reset of atlantoaxial dislocation. J. Postoperative CT reconstruction of the coronal site showed good reset of atlantoaxial dislocation. K. Postoperative CT 3D reconstruction showed reliable internal fixation and good reset of atlantoaxial fracture dislocation.



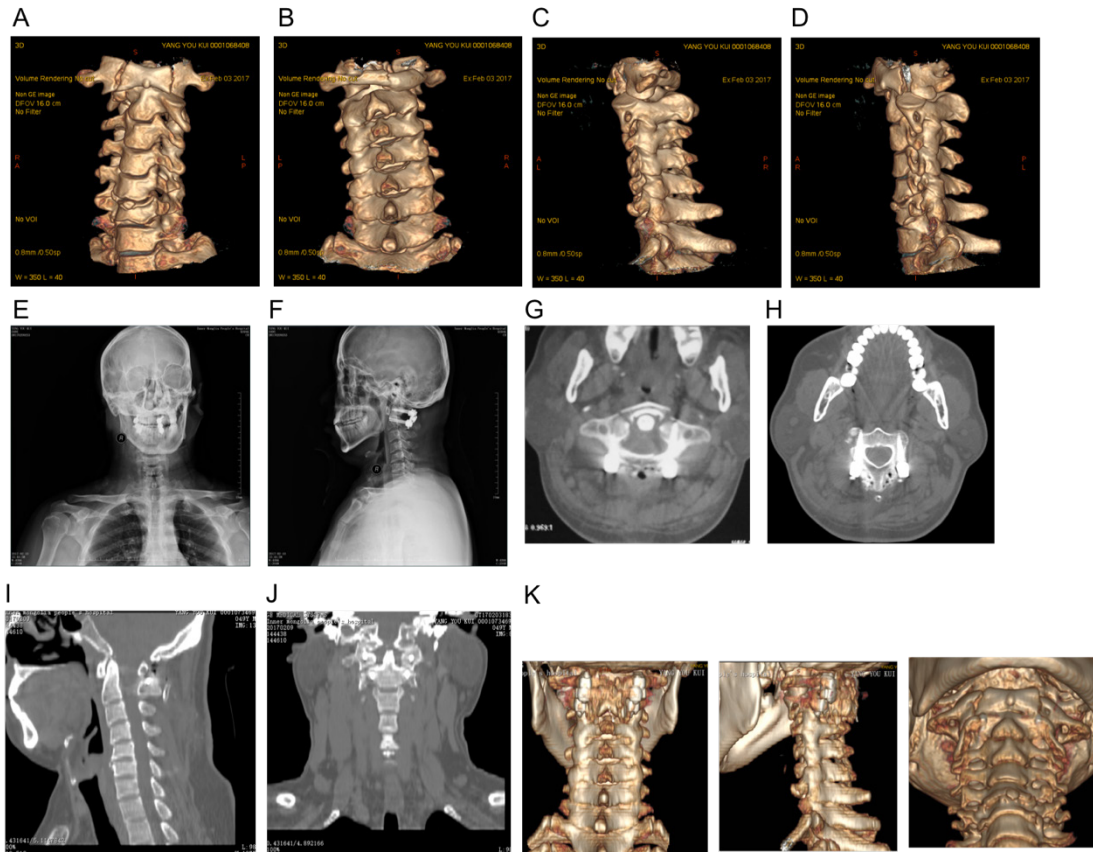
Supplementary Fig. 1. Typical case: a 39-year-old male with trauma caused by neck injury and limited activity. A. Anterior arch fracture of the atlas showed by CT. B. Posterior arch fracture of the atlas showed by CT. C. Anterior arch double fracture of the atlas showed by CT. D. Atlantoaxial dislocation showed by CT. E. Internal fixation in place showed by postoperative X-ray. F. Good reset of fracture dislocation. G. Accurate atlantoaxial fixation showed by postoperative CT plain scan. H. Reset of fracture dislocation showed by postoperative CT plain scan. I. Postoperative CT reconstruction of the sagittal site showed good reset of atlantoaxial dislocation. J. Postoperative CT reconstruction of the coronal site showed good reset of atlantoaxial dislocation. K. Postoperative CT 3D reconstruction showed reliable internal fixation and good reset of atlantoaxial fracture dislocation.



Supplementary Fig. 1. Typical case: a 39-year-old male with trauma caused by neck injury and limited activity. A. Anterior arch fracture of the atlas showed by CT. B. Posterior arch fracture of the atlas showed by CT. C. Anterior arch double fracture of the atlas showed by CT. D. Atlantoaxial dislocation showed by CT. E. Internal fixation in place showed by postoperative X-ray. F. Good reset of fracture dislocation. G. Accurate atlantoaxial fixation showed by postoperative CT plain scan. H. Reset of fracture dislocation showed by postoperative CT plain scan. I. Postoperative CT reconstruction of the sagittal site showed good reset of atlantoaxial dislocation. J. Postoperative CT reconstruction of the coronal site showed good reset of atlantoaxial dislocation. K. Postoperative CT 3D reconstruction showed reliable internal fixation and good reset of atlantoaxial fracture dislocation.



Supplementary Fig. 1. Typical case: a 39-year-old male with trauma caused by neck injury and limited activity. A. Anterior arch fracture of the atlas showed by CT. B. Posterior arch fracture of the atlas showed by CT. C. Anterior arch double fracture of the atlas showed by CT. D. Atlantoaxial dislocation showed by CT. E. Internal fixation in place showed by postoperative X-ray. F. Good reset of fracture dislocation. G. Accurate atlantoaxial fixation showed by postoperative CT plain scan. H. Reset of fracture dislocation showed by postoperative CT plain scan. I. Postoperative CT reconstruction of the sagittal site showed good reset of atlantoaxial dislocation. J. Postoperative CT reconstruction of the coronal site showed good reset of atlantoaxial dislocation. K. Postoperative CT 3D reconstruction showed reliable internal fixation and good reset of atlantoaxial fracture dislocation.



Supplementary Fig. 1. Typical case: a 39-year-old male with trauma caused by neck injury and limited activity. A. Anterior arch fracture of the atlas showed by CT. B. Posterior arch fracture of the atlas showed by CT. C. Anterior arch double fracture of the atlas showed by CT. D. Atlantoaxial dislocation showed by CT. E. Internal fixation in place showed by postoperative X-ray. F. Good reset of fracture dislocation. G. Accurate atlantoaxial fixation showed by postoperative CT plain scan. H. Reset of fracture dislocation showed by postoperative CT plain scan. I. Postoperative CT reconstruction of the sagittal site showed good reset of atlantoaxial dislocation. J. Postoperative CT reconstruction of the coronal site showed good reset of atlantoaxial dislocation. K. Postoperative CT 3D reconstruction showed reliable internal fixation and good reset of atlantoaxial fracture dislocation.