

Dear Author,

Here are the final proofs of your article. Please check the proofs carefully.

Please note that at this stage you should only be checking for errors introduced during the production process. Please pay particular attention to the following when checking the proof:

- Author names. Check that each author name is spelled correctly, and that names appear in the correct order of first name followed by family name. This will ensure that the names will be indexed correctly (for example if the author's name is 'Patel, J. ', she will be cited as ' Jane Patel ').
- Affiliations. Check that all authors are cited with the correct affiliations, that the author who will receive correspondence has been identified with an asterisk (*), and that all equal contributors have been identified with a well sign (#).
- Ensure that the main text is complete.
- Check that figures, tables and their legends are included and in the correct order.
- Look to see that queries that were raised during copy-editing or typesetting have been resolved.
- Confirm that all web links are correct and working.
- Ensure that special characters and equations are displaying correctly.
- Check that additional or supplementary files can be opened and are correct.

Changes in scientific content cannot be made at this stage unless the request has already been approved. This includes changes to title or authorship, new results, or corrected values.

How to return your corrections

Returning your corrections via email:

- Annotate the proof PDF with your corrections.
- Remember to include the journal title, manuscript number, and your name when sending your response via email.

After you have submitted your corrections, you will receive email notification from our production team that your article has been published in the final version. All changes at this stage are final. We will not be able to make any further changes after publication.

Kind regards,

Robotic-assisted transvesical excision of recurrent bladder leiomyoma with intraoperative ultrasound guidance

Ayman Ali^{a,*}, Daniel Wilby^a, Joni Dossantos^a, Richard Robinson^a

^a Urology Department, Portsmouth Hospitals NHS Trust, Portsmouth, United Kingdom.

Abstract

Leiomyoma of the urinary bladder is uncommon benign tumor with a wide range of clinical presentations. Surgical excision remains the definitive treatment of leiomyoma with excellent outcomes. Seldom literatures reported the use of robotic-assisted surgical techniques for its excision. A 51-year-old woman presented with frequent episodes of visible hematuria in consistence with lower urinary tract symptoms. The initial diagnosis was a urinary tract infection. However, symptoms did not resolve even with the proper antibiotics. After further investigations a soft tissue density mass measuring 20 × 23 × 20 mm within the left posterior wall of the urinary bladder extending towards the bladder neck was found. The histological finding of the transurethral resected biopsy of the mass revealed a benign submucosal leiomyoma of the bladder with no evidence of any malignancy. Using the Intuitive Da Vinci X system the tumor was excised using the ultrasound guidance to define the tumour margins, sparing the left ureteric orifice and ureter. The patient was discharged home on the day of surgery, with a urethral catheter in place. The catheter was successfully removed after 10 days, with cystogram prior confirming no leakage. The ureteric stent was removed by flexible cystoscopy two weeks later. The final histology was reported as a bladder leiomyoma with no evidence of malignant features and negative circumferential resection margins. Herein, in the current case we present a safe and effective technique for the excision of recurrent bladder leiomyoma using the robotic-assisted transvesical approach with intraoperative ultrasound guidance.

Keywords: Bladder, leiomyoma, robotic, partial cystectomy

Introduction

Bladder leiomyoma, a benign smooth muscle tumor, represents 0.43% of all bladder neoplasms. The clinical presentation is variable, depending on the location and size of the tumour [1]. Patients may present with hematuria or storage urinary symptoms; however, others may be asymptomatic discovering the lesion incidentally. The management of leiomyomas is mainly surgical, with different approaches from transurethral resection to open segmental resection or partial cystectomy described [2]. Bladder leiomyoma were exceptionally resected in certain female cases through trans-vaginal approach [3]. Laparoscopic

partial cystectomy was also suitable [4]. However, there are very limited data on the robotic excision of bladder leiomyoma [5].

Over the past 20 years, the application of robotic assisted technology in urological oncology has totally transformed the urologists' manner for approaching tumors. Being a feasible and safe technique with comparable oncologic outcomes and increased surgeon comfort, convinced urologists to make the robotic-assisted surgeries their top choice in urological cancers [6].

The use of robotic-assisted surgical techniques in urology offered many benefits over the established open surgery and laparoscopy. As, in addition to the benefit of 3D visualization of the surgical field, robotics allows good motion scaling, thus large movements at the console are translated into a very small motions at the operative site. Furthermore, robots terminated the fulcrum effect of laparoscopic surgery, in which the movement of the instrument tips went in an opposite direction to the surgeon's hand; however with robotic instruments the movement of instrument tips in the body goes in the same direction as the surgeon's hands in the console so that the degree

* Corresponding author: Ayman Ali

Mailing address: Portsmouth Hospitals NHS Trust, Portsmouth, United Kingdom; PO6 3LY.

Email: Ayman.Ali3@nhs.net

Received: 18 April 2023 / Revised: 28 June 2023

Accepted: 11 July 2023 / Published: XX September 2023

of freedom during the operation is enhanced [7]. In addition, robotics-assisted surgery eliminates tremors, reduces surgeon fatigue with more ergonomic positioning, so that allowing precise and smooth surgery. Accordingly, robotic assisted technique offers a higher dexterity and accuracy with less surgical complications [8].

There is an expanding use of the intraoperative ultrasound to handle and guide different intraoperative interventions. The main goal is the better visualization and location of lesions in order to provide interactive and precise information during surgery, thus, helping surgeons for a precise guidance during operation and in turn a potentially improving of the outcomes [9].

In our case, we introduce a robotic-assisted intravesical approach to excise bladder leiomyoma using intraoperative ultrasound guidance for accurate demarcation of lesion margins.

Case presentation

Our patient was a 51-year-old lady who presented with recurrent episodes of visible hematuria. She had no history of smoking, no occupational risk factors, and no family history of urological cancer. Her performance status was zero and she was on no medications. She was initially treated with antibiotics due to co-existing lower urinary tract symptoms thought to be due to urinary tract infection (UTI), but was subsequently referred to the urology clinic due to non-resolution of these symptoms and ongoing hematuria.

Initial flexible cystoscopy was inconclusive, due to poor views with a bladder full of debris. CT urography (CTU) demonstrated two relatively large distal ureteric stones measuring 15 mm and 10 mm in the longest diameter with proximal hydroureteronephrosis and non-obstructing renal stones in the contralateral kidney. The scan also identified a soft tissue density mass measuring 20 × 23 × 20 mm within the left posterior wall of the bladder extending toward the bladder neck (Figure 1).

She subsequently proceeded to rigid cystoscopy with transurethral resection biopsies and ureteroscopic LASER fragmentation of the right ureteric stones. Cystoscopy re-

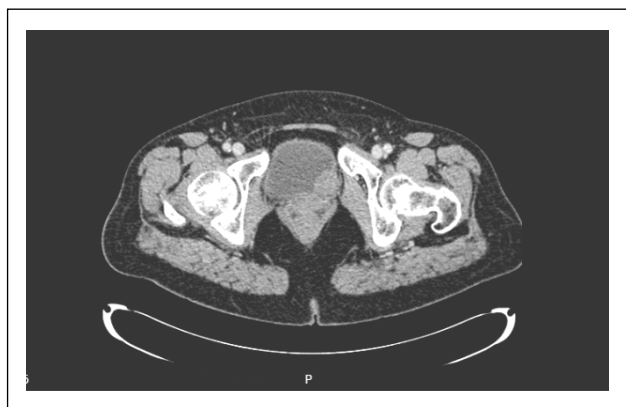

Figure 1. CTU showed the soft tissue density mass within the left posterior wall of the bladder extending toward the bladder neck.

vealed a normal bladder urothelium. The area of concern on the CTU appeared as a bulge with, normal urothelium adjacent to the left ureteric orifice. Loop resection biopsies were taken from the bulging area and sent for histological analysis. The tissue was relatively avascular on cutting.

Histology demonstrated a benign submucosal leiomyoma of the bladder with no evidence of any malignancy. Due to the anatomical position of the leiomyoma (adjacent to the ureteric orifice and bladder neck) and the absence of malignant features, a conservative management approach was adopted with a plan for surveillance cystoscopic assessment.

Her first check flexible cystoscopy revealed a calcified deposit in the region of her previous resection area with progression in size. She underwent further transurethral resection, which again reported benign leiomyoma on histology. She continued on conservative follow-up, with 6-monthly imaging with CTU and magnetic resonance imaging (MRI) demonstrating stable appearance of her bladder leiomyoma for almost 14 months. Despite this, she experienced increasing urinary storage symptoms and hematuria. Subsequent CTU showed an increase in both the intravesical and extravesical components and calcifications (Figure 2). In view of her increasingly bothersome symptoms and radiological progression, she was counseled regarding surgical excision. It was felt that continued conservative management risked further increase in size with resultant surgery being more complex with a higher risk of functional complications. The patient agreed to undergo robotic-assisted transvesical bladder leiomyoma excision.

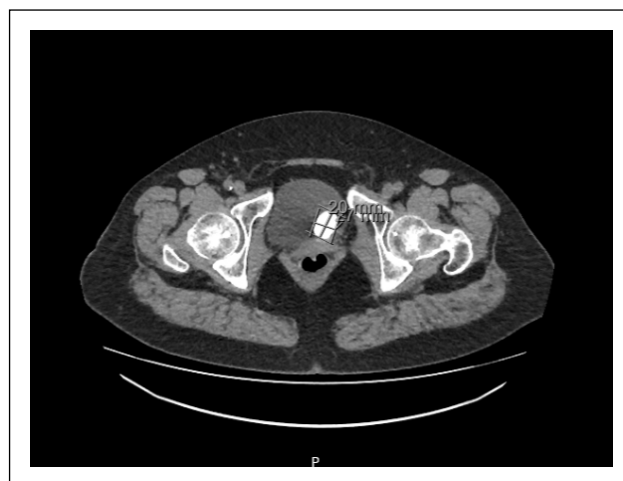

Figure 2. CTU showed an increase in both the intravesical and extravesical components and calcification.

Using the Intuitive Da Vinci X system, the patient was docked with the robot in 20° Trendelenburg using a standard cystectomy port placement, with a urinary catheter in place. The left side of the bladder was mobilized down to the endo-pelvic fascia with no division of the vascular pedicles. The bladder was then released anteriorly and dropped obliquely, leaving the right side undisturbed. The bladder was filled with saline and the tumor was charac-

terized using intracorporeal USS. The bladder was opened with a cranio-caudal oblique incision down to the anterior border of the tumor at the bladder neck, again with USS guidance. Due to the proximity of the tumor to the left ureteric orifice, a 6/24 JJ stent was inserted. The tumor was then excised using USS guidance to define the tumor margins, sparing the left ureteric orifice and ureter. The bladder was closed using a single layer 3/0 V-Loc with bladder neck reconstruction. The patient was discharged home on the day of surgery with a urethral catheter in place (Figure 3A–E).

The catheter was successfully removed after 10 days, with cystogram prior confirming no leakage (Figure 4). The ureteric stent was removed by flexible cystoscopy two weeks later. The final histology was reported as a bladder leiomyoma with no evidence of malignant features and negative circumferential resection margins. The patient was reviewed 6 weeks postoperatively and reported to be

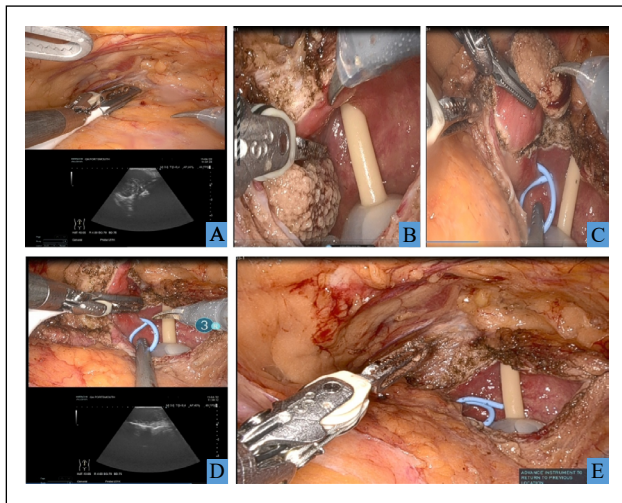


Figure 3. (A) Identification of the extent of the leiomyoma by ultrasound extravasically; (B) Cystostomy and visualisation of the boundaries of the lesion; (C) Stenting the left ureter and demarcation of the cutting margins; (D) confirmation of the margins by ultrasound intravesically prior to excision; (E) Bladder after excision of the lesion.

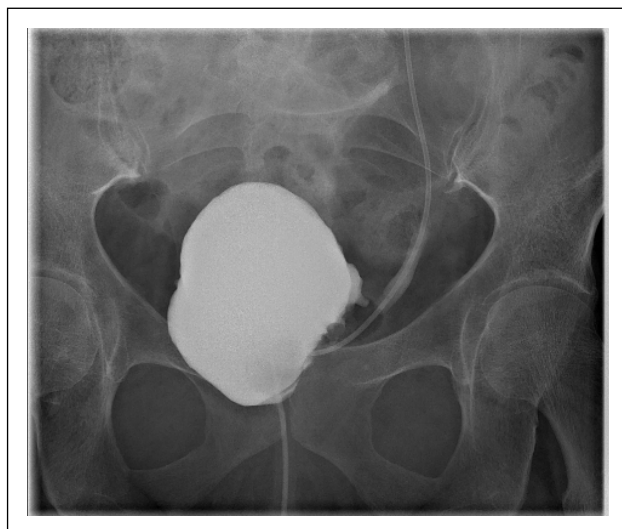

Figure 4. Cystogram prior catheter removal confirming no leakage.

fully continent with no ongoing lower urinary tract symptoms, and was discharged from follow-up.

Discussion

Despite being a rare neoplasm, bladder leiomyoma is the most common soft tissue benign non-epithelial tumor of the urinary bladder with variable clinical presentations [10]. Our patient had a submucosal bladder leiomyoma adjacent to the ureteric orifice and bladder neck. Nearly 80% of the affected patients suffered from symptoms ranging from irritative to obstructive symptoms with associated hematuria, which comes in line with the clinical presentation of our case [11]. On the other hand, other patients were rarely asymptomatic [12].

Although bladder leiomyoma has benign nature, it may behave as a malignant tumor, thus surgical removal using different surgical approaches is often preferred [11]. Surgical excision remains the definitive treatment for leiomyoma with excellent outcomes [1, 12]. However, laparoscopy, transurethral resection, and transvaginal resection using a hysteroscope are also other options.

Robotic-assisted excision of bladder leiomyomas provides the opportunity for this definitive treatment to be delivered in a minimally invasive way, providing all of the well-described advantages to patients of minimally invasive surgery (MIS) [5]. Literature on the excision of bladder leiomyomas using robotic approaches is limited. However, the use of the transvesical approach for leiomyoma excision was reported [13]. Interestingly, the use of intraoperative ultrasound guidance is a valuable tool that helps urologists to implement different complex robotic procedures with improved surgical outcomes [14]. Our procedure utilized the addition of intracorporeal USS guidance that gives the additional benefit of precise tumor identification, limiting the degree of bladder mobilization required, providing clear margin delineation, which should lead to a reduced risk of functional bladder sequelae and incomplete resection. Given the availability of robotics in modern urology, early use of robotic resection and reconstruction should be considered over other techniques and conservative management.

Our case sheds light on two clinical findings; first, the feasibility of robotic bladder leiomyoma excision using the transvesical approach; second, utilizing intraoperative ultrasound guidance during the procedure assisted us in performing a precise and safer excision of the leiomyoma. Hence, to the authors' knowledge, there are very few documented cases on the use of robotic-assisted bladder leiomyoma excision in the literature; however, our case is the first to describe the additional benefits of combining robotics with intracorporeal USS guidance.

Conclusion

Leiomyomas are rare benign neoplasms of the bladder, which present with variable symptoms and may even be

asymptomatic. Excision via a robotic transvesical approach offers a minimally invasive option for complete resection with minimal functional impact.

Declarations

Acknowledgments: NO grant or funding has been received to support this research from any funding agency.

Author contributions: Ali A: substantial contributions to the conception, design, methodology, drafting, writing, editing, reviewing, and final revision of the study; Wilby D: supervision, reviewing, and final revision of the work; Dossantos J: substantial contribution to the methodology of the work; Robinson R: supervision, methodology, reviewing, editing, and final revision of the work.

Financial Support and Sponsorship: None.

Conflict of interest statement: No conflict of interest.

Ethical Approval and Informed consent: According to institutional regulations, the patient has provided an informed consent for publication of images and information in this study. Any procedure performed was in accordance with the ethical standards of the institutional and national research committee and with the 1964 Helsinki Declaration and its later amendments or comparable ethical standards.

References

- Caliskan S, & Sungur M. Bladder Leiomyoma. *J Coll Physicians Surg Pak*, 2017, 27(3): 189-190.
- Zachariou A, Filiponi M, Dimitriadis F, Kaltsas A, & Sofikitis N. Transurethral resection of a bladder trigone leiomyoma: a rare case report. *BMC Urol*, 2020, 20(1): 152-157. [Crossref]
- Nagai N, Katayama Y, Iguchi M, & Esa A. [A case of urinary retention due to a female paraurethral leiomyoma]. *Hinyokika Kyo*, 1988, 34(4): 696-700.
- Murota T, Komai Y, Danno S, Fujita I, Kawakita M, & Matsuda T. Endoscopic partial cystectomy for bladder leiomyoma using retroperitoneoscopic and transurethral procedures. *Int J Urol*, 2002, 9(3): 190-192. [Crossref]
- Baird BA, Ericson CA, Augustus A, Geldmaker L, Wajswol E, & Young PR. Robotic transvesical bladder leiomyoma excision. *Urol Case Rep*, 2022, 43: 102054. [Crossref]
- Skolarus TA, Zhang Y, & Hollenbeck BK. Robotic surgery in urologic oncology: gathering the evidence. *Expert Rev Pharmacoecon Outcomes Res*, 2010, 10(4): 421-432. [Crossref]
- Kim VB, Chapman WH, Albrecht RJ, Bailey BM, Young JA, Nifong LW, et al. Early experience with telemanipulative robot-assisted laparoscopic cholecystectomy using da Vinci. *Surg Laparosc Endosc Percutan Tech*, 2002, 12(1): 33-40. [Crossref]
- Murphy D, Challacombe B, Khan MS, & Dasgupta P. Robotic technology in urology. *Postgrad Med J*, 2006, 82(973): 743-747. [Crossref]
- Porpiglia F, Checcucci E, Amparore D, Piramide F, Volpi G, Granato S, et al. Three-dimensional augmented reality robot-assisted partial nephrectomy in case of complex tumours (PADUA ≥ 10): a new intraoperative tool overcoming the ultrasound guidance. *Eur Urol*, 2020, 78(2): 229-238. [Crossref]
- Park JW, Jeong BC, Seo SI, Jeon SS, Kwon GY, & Lee HM. Leiomyoma of the urinary bladder: a series of nine cases and review of the literature. *Urology*, 2010, 76(6): 1425-1429. [Crossref]
- Yoshioka T, Kawakita M, & Kameoka H. Cystoscope-assisted laparoscopic enucleation of a large progressive bladder leiomyoma. *J Endourol Case Rep*, 2019, 5(3): 120-123. [Crossref]
- Tobias-Machado M, Pazeto CL, & Borges RC. Robot-assisted transvesical partial cystectomy for leiomyoma of bladder trigone. *Int Braz J Urol*, 2020, 46(2): 300. [Crossref]
- Gok A. Transurethral resection of a large urinary bladder leiomyoma: a rare case report. *Urol J*, 2017, 14(4): 4052-4054.
- Ukimura O, Okihara K, Kamoi K, Naya Y, Ochiai A, & Miki T. Intraoperative ultrasonography in an era of minimally invasive urology. *Int J Urol*, 2008, 15(8): 673-680. [Crossref]

Cite this article as: Ali A, Wilby D, Dossantos J & Robinson R. Robotic-assisted transvesical excision of recurrent bladder leiomyoma with intraoperative ultrasound guidance *Uro-Technology Journal*, 2023, 7(3): XX-XX. doi: 10.31491/UTJ.2023.09.XXX

Author Query Form

Dear Author,

During the copy-editing of your paper, the following queries arose.

Please refer to the query reference call out numbers in the page proofs and respond to each by marking the necessary comments using the PDF annotation tools.

Please remember illegible or unclear comments and corrections may delay publication.

Many thanks for your assistance.

QueryReference	Query	Remark
Q1	Please check that all author information is correct?	
Q2	Please confirm that the corresponding author's address is correct?	
Q3	Please check if the Table and Figure are correct?	
Q4	Please confirm whether there are any content and spelling errors in the full text?	
Q5	Please check if the References are correct?	