

Cover letter

Dear Editor/s

I am sending you our case report entitled "Robotic assisted transvesical excision of recurrent bladder leiomyoma with intraoperative ultrasound guidance" for a consideration of publication in your respectful journal, Uro-Technology Journal.

We have submitted our work in the Uro-Technology Journal where we hope to be accepted and published because our current case study, to the best of the authors' knowledge, is the only documented case on the use of robotic assisted bladder leiomyoma excision and the first to describe the additional benefits of combining robotics with intracorporeal USS guidance. The manuscript includes 4 figures.

We confirm that this case study has not been published in part or whole ant any journal and not under consideration for publication elsewhere.

We confirm that all authors have reviewed, approved, and consented to the submission in the Uro-Technology Journal.

We confirm that there are no any potential competing interests.

Best regards,

The authors

Corresponding author: *Ayman Ali*; senior clinical fellow in robotic urology at Portsmouth hospitals University NHS trust, Portsmouth, United Kingdom.

E-mail: Ayman.Ali3@nhs.net.

Title page

Robotic assisted transvesical excision of recurrent bladder leiomyoma with intraoperative ultrasound guidance

Running Head: A case of robotic assisted bladder leiomyoma excision with the beneficial guidance of intraoperative ultrasound.

Authors:

Ayman Ali^{a}, Daniel Wilby^a, Joni Dossantos^a, Richard Robinson^a*

Affiliations:

^a Urology Department, Portsmouth Hospitals NHS Trust, Portsmouth, United Kingdom.

***Corresponding Author details:**

Name: Ayman Ali

E-mail: Ayman.Ali3@nhs.net

Address: Portsmouth Hospitals NHS Trust, Portsmouth, United Kingdom; PO6 3LY.

Robotic assisted transvesical excision of recurrent bladder leiomyoma with intraoperative ultrasound guidance

Abstract

Background: Leiomyoma of the urinary bladder is uncommon benign tumour with a wide range clinical presentation. Surgical excision remains the definitive treatment of leiomyoma with excellent outcomes. Seldom literatures reported the use of robotic assisted surgical techniques for its excision. **Case description:** A 51 years old woman presented with frequent episodes of visible haematuria in consistence with lower urinary tract symptoms. The initial diagnosis was urinary tract infection however, symptoms did not resolve even with the proper antibiotics. After further investigations a soft tissue density mass measuring 20×23×20 mm within the left posterior wall of the urinary bladder extending towards the bladder neck was found. The histological finding of the transurethral resected biopsy of the mass revealed a benign submucosal leiomyoma of the bladder with no evidence of any malignancy. Using the Intuitive Da Vinci X system the tumor was excised using the ultrasound guidance to define the tumour margins, sparing the left ureteric orifice and ureter. The patient was discharged home on the day of surgery, with a urethral catheter in place. The catheter was successfully removed after 10 days, with cystogram prior confirming no leakage. The ureteric stent was removed by flexible cystoscopy two weeks later. The final histology was reported as a bladder leiomyoma with no evidence of malignant features and negative circumferential resection margins. **Conclusion:** Herein, in the current case we present a safe and effective technique for the excision of recurrent bladder leiomyoma using the robotic assisted transvesical approach with intraoperative ultrasound guidance.

Keywords: Bladder, Leiomyoma, Robotic, partial cystectomy.

Introduction

Bladder leiomyoma, a benign smooth muscle tumour, represents 0.43% of all bladder neoplasms. Clinical presentation is variable, depending on location and size of the tumour^[1]. Patients may present with haematuria or storage urinary symptoms, however, others may be asymptomatic discovering the lesion incidentally. The management of leiomyomas is mainly surgical, with different approaches from transurethral resection to open segmental resection or partial cystectomy described. There is a very limited data on the robotic excision of bladder leiomyoma [2].

In our case, we introduce robotic assisted intravesical approach to excise bladder leiomyoma, using intraoperative ultrasound guidance for accurate demarcation of lesion margins.

Case presentation

Our patient was 51 years old lady who presented with recurrent episodes of visible haematuria. She had no history of smoking, no occupational risk factors and no family history of urological cancer. Her performance status was zero and she was on no medications. She was initially treated with antibiotics due to co-existing lower urinary tract symptoms thought to be due to UTI, but subsequently referred to the urology clinic due to non-resolution of these symptoms and ongoing haematuria.

Initial flexible cystoscopy was inconclusive, due to poor views with a bladder full of debris. CT urography (CTU) demonstrated two relatively large distal ureteric stones measuring 15mm and 10 mm in the longest diameter with proximal hydroureteronephrosis and non-obstructing renal stones in the contralateral kidney. The scan also identified a soft tissue density mass measuring 20×23×20 mm within the left posterior wall of the urinary bladder extending towards the bladder neck (Fig. 1).

She subsequently proceeded to rigid cystoscopy with transurethral resection biopsies and ureteroscopic LASER fragmentation of the right ureteric stones. Cystoscopy revealed normal bladder urothelium. The area of concern on the CTU appeared as a bulge with, normal urothelial, adjacent to the left ureteric orifice. Loop resection biopsies were taken from the bulging area and sent for histological analysis. The tissue was relatively avascular on cutting.

Histology demonstrated a benign submucosal leiomyoma of the bladder with no evidence of any malignancy. Due to the anatomical position of the leiomyoma (adjacent to ureteric orifice and bladder neck) and the absence of malignant features, a conservative management approach was adopted, with plan for surveillance cystoscopic assessment.

Her first check flexible cystoscopy revealed a calcified deposit in the region of her previous resection area with progression in its size. She underwent further transurethral resection which again reported benign leiomyoma on histology. She continued on conservative follow up, with 6 monthly imaging with CTU and MRI demonstrating stable appearance of her bladder leiomyoma for almost 14 months. Despite this she experienced increasing storage urinary symptoms and haematuria. Subsequent CTU showed an increase in both the intravesical and extravesical components and calcification. (Fig.2). In view of her increasingly bothersome symptoms and radiological progression, she was counselled regarding surgical excision. It was felt that continued conservative management risked further increase in size with resultant surgery being

more complex with a higher risk of functional complications. The patient agreed to undergo robotic assisted transvesical bladder leiomyoma excision.

Using the Intuitive Da Vinci X system the patient was docked with the robot in 20° Trendelenburg using a standard cystectomy port placement, with a urinary catheter in place. The left side of bladder was mobilised down to endo-pelvic fascia, with no division of the vascular pedicles. The bladder was then released anteriorly and dropped obliquely, leaving right side undisturbed. The bladder was filled with saline and the tumour characterised using intracorporeal USS. The bladder was opened with a cranio-caudal oblique incision down to the anterior border of the tumour at the bladder neck, again with USS guidance. Due to the proximity of the tumour to the left ureteric orifice a 6/24 JJ stent was inserted. The tumour was then excised using USS guidance to define the tumour margins, sparing the left ureteric orifice and ureter. The bladder closed using a single layer 3/0 V-Loc, with bladder neck reconstruction. The patient was discharged home on the day of surgery, with a urethral catheter in place. (Fig.3A, 3B, 3C, 3D, 3E).

The catheter was successfully removed after 10 days, with cystogram prior confirming no leakage (Fig. 4). The ureteric stent was removed by flexible cystoscopy two weeks later.

The final histology was reported as a bladder leiomyoma with no evidence of malignant features and negative circumferential resection margins.

The patient was reviewed 6 weeks post operatively and reported she was fully continent with no ongoing lower urinary tract symptoms, and was discharged from follow up.

Discussion

Despite being a rare neoplasm, bladder leiomyoma is the most common soft tissue benign non-epithelial tumour of the urinary bladder with variable clinical presentations [3].

Surgical excision remains the definitive treatment of leiomyoma with excellent outcomes [1, 4]. Robotic assisted excision of bladder leiomyomas provides the opportunity for this definitive treatment to be delivered in a minimally invasive way, providing all of the well described advantages to patients of minimally invasive surgery (MIS) [5]. The addition of intracorporeal USS guidance gives the additional benefit of precise tumour identification, limiting the degree of bladder mobilisation required, providing clear margin delineation, which should lead to a reduced risk of functional bladder sequelae and incomplete resection. Given the availability of robotics in modern urology, early use of robotic resection and reconstruction should be considered over other techniques and conservative management.

To the authors' knowledge, there is only one documented case on the use of robotic assisted bladder leiomyoma excision in the literature, and our case is the first to describe the additional benefits of combining robotics with intracorporeal USS guidance.

Conclusion

Leiomyomas are rare benign neoplasms of the bladder, which present with variable symptoms and may even be asymptomatic. Excision via a robotic transvesical approach offers a minimally invasive option for complete resection with minimal functional impact.

Declarations

Acknowledgements

NO grant or funding has been received to support this research from any funding agency.

Author contributions:

Substantial contributions to the conception, design, methodology, drafting, writing, editing, reviewing and final revision of the study: **Ali A**; Supervision, reviewing and final revision of the work: **Wilby D**; Substantial contribution to the methodology of the work: **Dossantos J**; Supervision, methodology, reviewing, editing and final revision of the work: **Robinson R**.

Financial Support and Sponsorship

None

Conflict of interest statement

No conflict of interest.

Ethical Approval and Informed consent

According to institutional regulations, the patient has provided an informed consent for publication of images and information in this study. Any procedure performed was in accordance with the ethical standards of the institutional and national research committee and with the 1964 Helsinki Declaration and its later amendments or comparable ethical standards.

References

- [1] Caliskan S, Sungur M. Bladder Leiomyoma. J Coll Physicians Surg Pak. 2017;27(3):189-190. PMID: 28406781. <https://pubmed.ncbi.nlm.nih.gov/28406781/>
- [2] Baird BA, Ericson CA, Augustus A, Geldmaker L, Wajswol E, Young P R , Robotic transvesical bladder leiomyoma excision, Robotic transvesical bladder leiomyoma excision. Urology Case Reports, 2022; (43),102054. doi.org/10.1016/j.eucr.2022.102054 <https://www.ncbi.nlm.nih.gov/pmc/articles/PMC8956799/>
- [3] Park J W., Jeong B C., Seo SI., Jeon SS., Kwon GY., Lee HM. Leiomyoma of the Urinary Bladder: A Series of Nine Cases and Review of the Literature. Urology, 2010; 76(6), 1425-1429. doi:10.1016/j.urology.2010.02.046 <https://pubmed.ncbi.nlm.nih.gov/20947147/>
- [4] Yoshioka Y, Kawakita M, Kameoka H. Cystoscope-Assisted laparoscopic enucleation of a large progressive bladder leiomyoma. J Endourol Case Rep, 2019; 5 (3), pp. 120-123. <https://pubmed.ncbi.nlm.nih.gov/32775643/>
- [5] Marcos Tobias-Machado, Cristiano Linck Pazeto , Rafael Castilho Borges. Robot-assisted transvesical partial cystectomy for leiomyoma of bladder trigone. Int Braz J Urol Mar-Apr 2020;46(2):300. Doi: 10.1590/S1677-5538.IBJU.2018.0801. <https://pubmed.ncbi.nlm.nih.gov/32022531/>

Figures

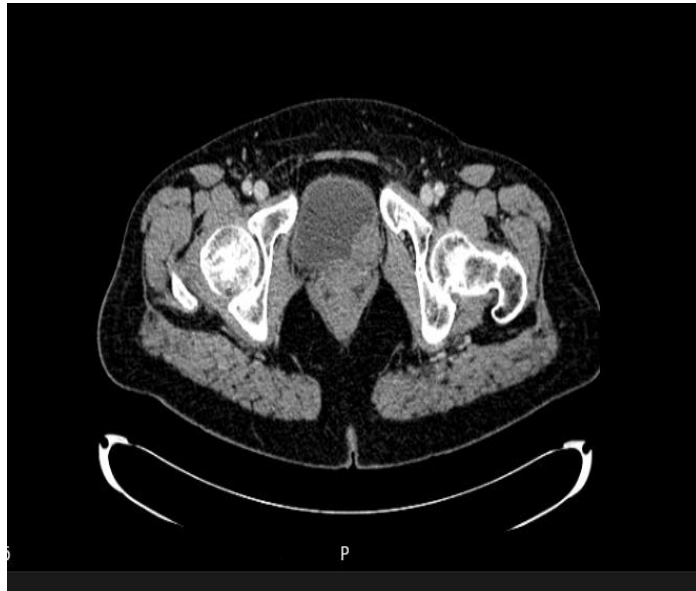

Figure (1) CTU showed the soft tissue density mass within the left posterior wall of the urinary bladder extending towards the bladder neck.

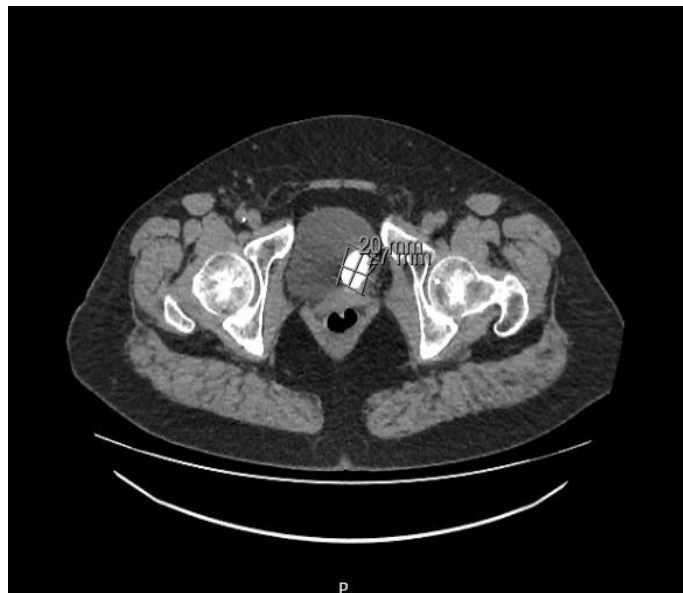

Figure (2): CTU showed an increase in both the intravesical and extravesical components and calcification.

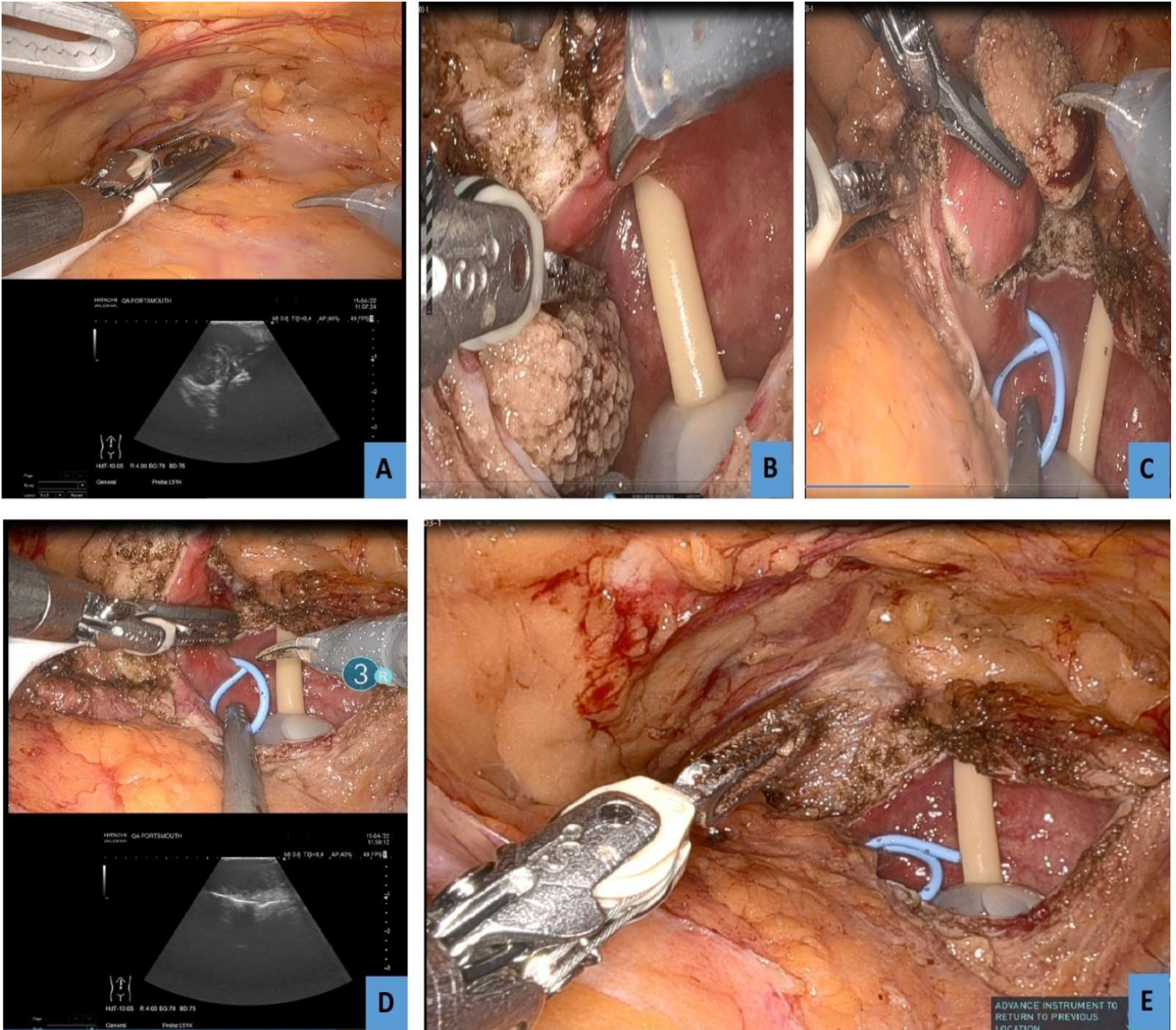


Figure (3): (A) Identification of the extent of the leiomyoma by Ultrasound extravasically; (B) cystostomy and visualisation of the boundaries of the lesion; (C) Stenting the left ureter and demarcation of the cutting margins; (D) confirmation of the margins by ultrasound intravesically prior to excision; (E): Bladder after excision of the lesion.

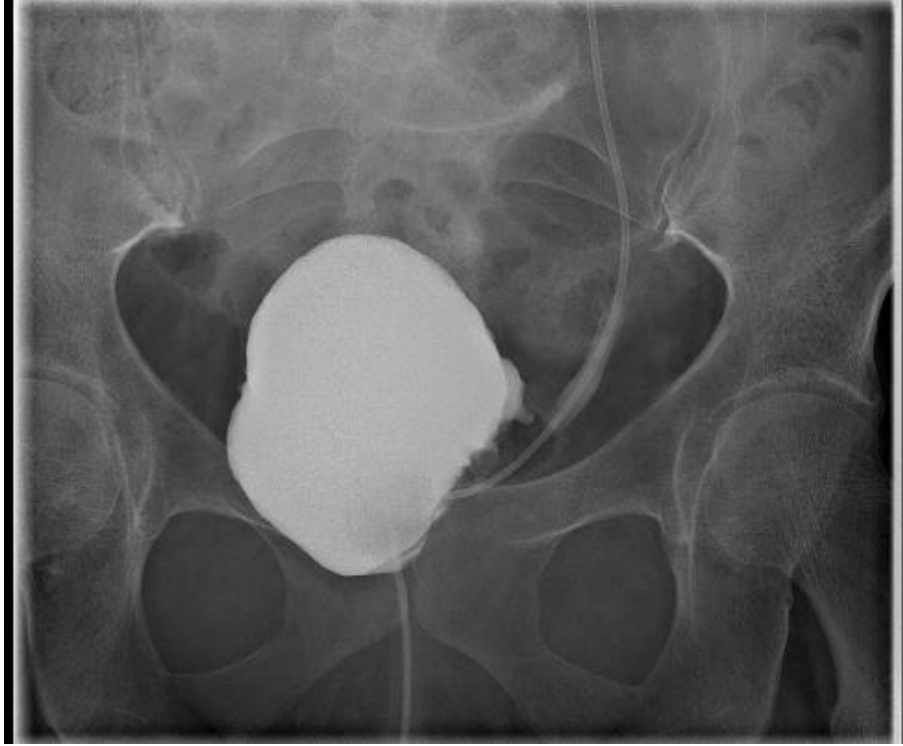

Figure (4): Cystogram prior catheter removal confirming no leakage